

Judul Artikel : Acute Toxicity Study of Porang (*Amorphophallus oncophyllus*) Flour Macerated with *Strobilanthes crispus* in Wistar Rats
Nama Jurnal : Open Access Macedonian Journal of Medical Sciences
ISSN : 1857-9655
Tahun Terbit : 2021
Penerbit : Scientific Foundation SPIROSKI
Volume : 9
Nomor : A
No. Halaman : 976-981
Url Cek Plagiasi : http://elibrary.almaata.ac.id/2470/27/P3_turnitin.pdf
Url Index : <https://www.scopus.com/sourceid/21100824403>
Url Jurnal : <https://doi.org/10.3889/oamjms.2021.6813>

SUBMISSION



[← Back to Submissions](#)

6813 / A'yun et al. / Acute Toxicity Study of Porang (*Amorphophallus oncophyllus*) Flour Macerated with *Strobilanthes crispus* in Wista Library

Workflow **Publication**

Submission Review Copyediting Production

Submission Files

[Q Search](#)

 45889	Veriani Aprilia_title page_macedonian journal of medical science.docx	July 9, 2021	Manuscript Title Page
 45890	Veriani Aprilia_manuscript main text_macedonian journal of medical science.docx	July 9, 2021	Manuscript Main Text

[Download All Files](#)

Pre-Review Discussions

[Add discussion](#)

Name	From	Last Reply	Replies	Closed
Comments for the Editor	vaprilia 2021-07-09 11:49 AM	-	0	<input type="checkbox"/>

Acute Toxicity Study of Porang (*Amorphophallus oncophyllus*) Flour Macerated with *Strobilanthes crispus* in Wistar Rats

Rizka Qurrota A'yun¹, Uswatun Hasanah¹, Hamam Hadi², Mustofa³, Eva Nurinda⁴, Yulinda Kurniasari¹, Veriani Aprilia¹

¹*Department of Nutrition, Faculty of Health Sciences, Universitas Alma Ata, Jl. Brawijaya No. 99, Tamantirto, Kasihan, Bantul, Yogyakarta 55183, Indonesia*

²*Graduate School of Public Health, Universitas Alma Ata, Jl. Brawijaya No. 99, Tamantirto, Kasihan, Bantul, Yogyakarta 55183, Indonesia*

³*Department of Pharmacology & Therapy, Faculty of Medicine, Public Health, and Nursing, Universitas Gadjah Mada, Jalan Farmako, Sekip Utara, Yogyakarta 55281, Indonesia*

⁴*Department of Pharmacy, Faculty of Health Sciences, Universitas Alma Ata, Jl. Brawijaya No. 99, Tamantirto, Kasihan, Bantul, Yogyakarta 55183, Indonesia*

Corresponding author: Veriani Aprilia, *Department of Nutrition, Faculty of Health Sciences, Universitas Alma Ata, Jl. Brawijaya No. 99, Tamantirto, Kasihan, Bantul, Yogyakarta 55183, Indonesia.*
E-mail: verianiaprilia@almaata.ac.id. ORCID iD: 0000-0002-6231-6487

Short title: Acute Toxicity Study of Porang Macerated with *Strobilanthes crispus*

Funding: This research was supported by Universitas Alma Ata

Acute Toxicity Study of Porang (*Amorphophallus oncophyllus*) Flour Macerated with *Strobilanthes crispus* in Wistar Rats

Abstract

BACKGROUND: Porang (*Amorphophallus oncophyllus*) is a local tuber food that high in bioactive compound glucomannan. Its uses are limited due to oxalate acid content which poses health risks. *Strobilanthes crispus* leaves could reduce the level of calcium oxalate in porang. However, there is still no study to prove its safety.

AIMS: This study aimed to investigate the acute oral toxicity study of porang (*Amorphophallus oncophyllus*) macerated with *Strobilanthes crispus* based on observation of mortality rate (LD50), the changes in behavior during 72 h, renal and hepatic function such as urinary protein, SGOT, and SGPT levels of Wistar rat (*Rattus norvegicus*)

METHODS: An acute toxicity test was conducted based on the OECD 420 Fixed-Dose Procedure Guideline that consists of preliminary and main studies. For the preliminary study, rats were divided into control and 5 treatment groups with the dosage of 50, 300, 2000, 5000 mg/kg bodyweight (BW) for each natural porang flour/NPF and *S. crispus*-macerated porang flour/SPF. For the main study, rats were divided into 4 groups, those were NPF and SPF with the dosage of 2000 and 5000 mg/kg BW. Levels of urinary protein and blood serum SGOT and SGPT levels were measured at 0, 24, and 72 after treatment.

RESULTS: The acute toxicity study showed that porang and porang macerated with *S. crispus* were not toxic until the highest dose of 5000 mg/kg BW. It was proved by the absence of LD50, no change in behavior, no weight losses, and also the results of biochemical tests, such as urinary protein, SGOT, and SGPT which were still in the normal range.

CONCLUSION: Porang flour and *S.crispus*-macerated porang flour were concluded as non-toxic food based on acute toxicity study.

Keywords: *Amorphophallus oncophyllus*, *Strobilanthes crispus*, LD50, urinary protein, SGOT, SGPT

Introduction

Porang or iles-iles is included in the genus of *Amorphophallus*. These plants wildly grow in the jungle, under the bamboo tree, along the riverside, and mountain slope [1]. Porang tuber (*Amorphophallus oncophyllus*) contains glucomannan or known as mannan. Glucomannan is a water-dissolved food fiber that is low in calories and has a special function for diet, so that it has been widely used for food products, such as nuggets, noodles, ice cream, etc [2–4]. The food containing glucomannan reduced cholesterol level, blood sugar, and hypertension [5]. Its relatively low glycemic index, which was

20.6, could decrease blood sugar level and made this tuber was good to be consumed by diabetic patients [6].

Several studies had proven that there was a functional compound in glucomannan that affected several mechanisms in organism bodies. Haihong Chen in his study showed that konjac glucomannan as a nutraceutical can be used to boost the therapy of diabetes type 2 through lipid metabolism improvement [7], while Jialin Zheng reported that glucomannan worked in synergy with metformin to increase its hypoglycemia effect [8].

Even though it had been proven that there were many benefits of glucomannan, the utilization of porang tuber as the source of glucomannan is still low. This is caused by the homemade product of porang still has the weakness, that is itchy when consumed. This itchiness is caused by the content of oxalate [9–12]. Oxalate acid consumption in a high number increased blood creatinine and urea levels [9,13]. It also decreased the bioavailability of calcium inside the body, formed kidney stones, can cause corrosion of the mouth and gastrointestinal tract, kidney failure, and hematuria [14]. Various efforts had been carried out to reduce the level of calcium oxalate level in porang tuber, both mechanically using stamp mill and blower, ball mill, also chemically using NaCl, ethanol, and aluminum sulfate [11,12,15–17]. The research using natural or herbal ingredients in reducing oxalate calcium content is still limited. In a previous study, ethanol extract of *Strobilanthes crispus* leaves reduced the level of calcium oxalate in porang flour [18], but it still needs to be proved before consumption for its safety. Therefore, in vivo toxicity test is needed to be carried out [19].

A toxicity test is a set of analyses to detect the toxic effect of a substance on the biological system and to obtain typical dose-response data from the test preparation [20]. In addition, a toxicity test can be carried out to determine the toxic effects on the vital organs of the animal, such as the kidneys and liver. One of the kidney functions is to excrete foreign compounds such as drugs, food, pesticides, and other non-nutritional exogenous materials that enter the body [21]. The study of the level of porang toxicity was reported on porang tubers [22,23], but its combination with *S. crispus* needs to be studied further.

In this study, an acute toxicity test was conducted by observing the mortality rate (LD50) and the changes in behavior during 72 h. To confirm the kidney and liver function, the urea protein tests, kidney histopathology, and biochemical tests of aminotransferase enzyme activity (SGOT and SGPT) were also done.

Materials and methods

Plant materials and sample preparation

Porang was purchased from the farmer in Madiun, East Java. It was directly processed into flour at the laboratory. Porang flour macerated with *S. crispus* was then produced based on the Patent Application No. S00202006668 [19].

Experimental animals

Non-pregnant female Wistar (*Rattus Norvegicus*) rats weighing 110-180 g with the age of 8-12 weeks were used in this acute study. For the preliminary study, eleven rats were used. Each of them was represented as a treatment group based on the dose of oral feeding, i.e. control (distilled water treatment), NPF1 (natural porang flour), NPF2, NPF3, NPF4, NPF5, and SPF1 (*S. crispus*-macerated porang flour), SPF2, SPF3, SPF4, SPF5 for the dose of 50, 300, 2000, 5000 mg/kg of bodyweight (BW), respectively. For the main study, twenty rats were divided into 4 groups, i.e. NPF6 (dose of 2000 mg/kg BW), NPF7, SPF6, ad SPF7.

An acute toxicity study was conducted based on the Organization of Economic Co-Operation and Development (OECD) Guideline 420 for testing chemicals. The procedures consisted of two steps, those were preliminary and main analysis. For preliminary analysis, the rats were orally administered with porang flour or *S. crispus*-macerated porang flour with doses of 5, 50, 300 mg/kg BW. If there was no mortality, the dose was increased up to 2000 mg/kg BW. For the main analysis, the doses used were 2000 mg/kg BW and 5000 mg/kg BW [24].

The acclimatization of animals was 5 d and fed with free access to standard laboratory diet and ad-libitum water. They were then fasted for 18 h before administered with the flours. The mortality, any injury or illness, physical appearance, behavior changes (step backward, walk with the stomach, sleepy), diarrhea were observed visually after the first 30 min and every 1 h for 24 h. If there was no sign of toxicity, the test was completed until 72 h. The bodyweight of rats was monitored at the beginning and the end of the analysis. The urine and blood samples were collected before treatment, 24 h and 72 h after treatment for determining the urinary protein levels, SGOT (serum glutamic oxaloacetic transaminase), and SGPT (serum glutamic pyruvic transaminase) levels, respectively. At the end of the study, rats were euthanized by decapitation, the kidney organs were excised carefully, then preserved in 10% buffered formalin before the histopathological study.

Urinary protein levels were analyzed by the pyrogallol red-molybdate method. SGOT and SGPT were analyzed by Optimized UV-test according to IFCC (International Federation of. Clinical Chemistry and Laboratory Medicine) [20].

Statistical analysis

Data were performed by mean values, followed by statistical analysis used SPSS ver. 16. The differences between samples were tested by analysis of variance (ANOVA) with Duncan's multiple range test. Differences were significant when $p < 0.05$.

Results and discussion

Acute oral toxicity study

The first acute oral toxicity study was preliminary. This study was important to find the starting dose that must be done in the main study because there was still no study about the toxicity of porang with the combination of *S. crispus*. The study showed that

there was no mortality (LD50), injury, physical appearance, or behavior changes from the first 30 min until 72 h observations, for both NPF and SPF groups. The data were used as the reason to conduct the main study with the dose of 2000 mg/kg BW and 5000 mg/kg BW.

The main study was also showed no toxicity sign and mortality in all groups. Because the maximum dose did not cause mortality, LD50 was stated as apparent LD50. Based on The Hodge and Sterner Toxicity Scale, porang both natural and macerated with *S. crispus* were categorized as practically non-toxic due to no mortality (LD50) at the administration dose of 5000-15000 mg/kg BW [25].

Bodyweight of rats

Figure 1 showed the bodyweight of rats during 72 h of preliminary study. The bodyweight of rats in this preliminary test did not show the weight loss that was in line with the results of the main study [13]. The absence of weight loss indicated that their growth was normal or there was no indication of impaired absorption of nutrients due to the oral administration of porang flour both natural and macerated with *S. crispus*.

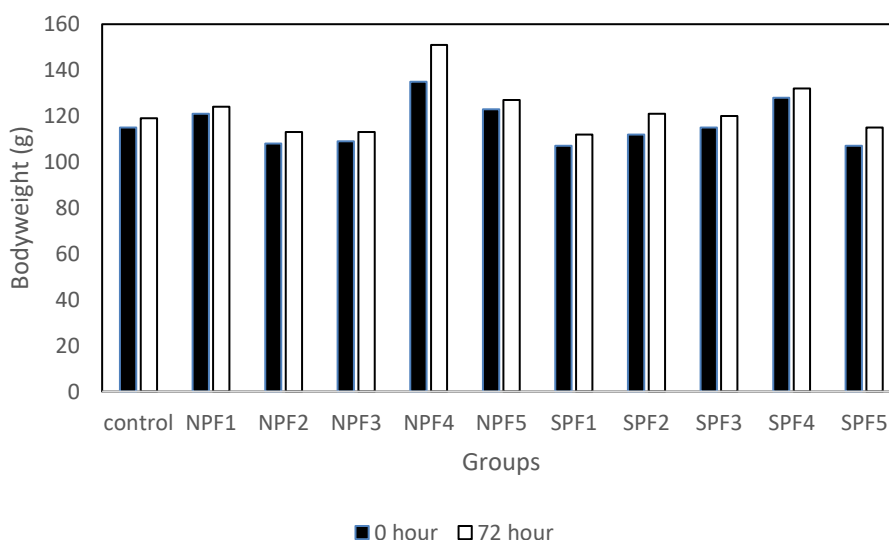


Figure 1: Bodyweight of rats in acute toxicity study of natural porang and *S. crispus*-macerated porang flour (control=distilled water treatment, NPF=natural porang flour, SPF= *S. crispus*-macerated porang flour. NPF1, NPF2, NPF3, NPF4, NPF5 and SPF1, SPF2, SPF3, SPF4, SPF5 for the dose of 50, 300, 2000, 5000 mg/kg BW in preliminary study, respectively).

Urinary protein levels and histopathological examination of kidney organ

The effect of the administration of porang flour on urinary protein levels was shown in Table 1. All groups showed urinary levels under 200 mg/L that categorized as normal levels [26]. However, there was an increase observed in NPF7 and SPF7 both in 24 h and 72 h of administration and NPF6 after 72 h of administration ($p < 0.05$). It indicated that the elevation of protein levels may be seen at a shorter time when a higher dose was applied.

The increase of protein levels in the urine indicated a progression to a reduction in renal performance [27]. This study was relevant to the previous publication of the same study which showed an increase in urea and creatinine levels which can be used as an indicator of kidney function/performance [9,13]. In another study, the administration of the herbal medicine of galohgor also showed an increase in urea level, creatinine, and urinary protein [28]. In this study, the decrease was still within the normal range, therefore it is necessary to confirm with further toxicity tests of sub chronic and others to find out whether in a longer period of studies there will be a gradual reduction in kidney performance.

In this study, there was no difference in urea protein levels between the NPF and SPF groups, which indicated that immersion in *S. crispus*, which is one of the herbal medicines, did not affect increasing urea protein levels. However, porang flour contains components that can cause the risk of damage to the kidneys, namely calcium oxalate. Calcium oxalate had an impact on mechanical abrasion of the gastrointestinal tract and renal smooth tubules [29]. In another study, the administration of herbal medicine caused acute tubular necrosis or fibrotic interstitial nephritis that occurred rapidly and progressively. This syndrome was characterized by progressive renal failure, the discovery of a lot of urine sediment, shrinkage of kidney size with mild proteinuria, and was associated with the incidence of urothelial cancer [30,31].

Table 1: Urinary protein levels of rats in acute toxicity study of porang and *S. crispus* macerated porang flour

Urinary Protein (mg/L)	NPF6 (mean±SD)	SPF6 (mean±SD)	NPF7 (mean±SD)	SPF7 (mean±SD)
24 h				
Pre	62.32 ± 7.23	59.45 ± 4.78	60.33 ± 6.03	60.33 ± 2.29
Post	62.74 ± 6.83	59.29 ± 3.90	77.77 ± 2.11	74.92 ± 4.73
P-value ¹	0.235	0.783	0.004*	0.005*
Δ	0.42 ± 0.68	-0.16 ± 1.18	17.43 ± 6.68	14.59 ± 5.68
P-value ²		0.370		0.489
72 h				
Pre	62.32 ± 7.23	59.45 ± 4.78	60.33 ± 6.03	60.33 ± 0.29
Post	65.91 ± 5.60	60.13 ± 4.21	80.50 ± 1.99	76.48 ± 5.21
P-value ¹	0.009*	0.217	0.002*	0.005*
Δ	3.59 ± 1.68	0.68 ± 1.04	20.17 ± 6.41	16.15 ± 6.30
P-value ²		0,011*		0.346

*Significant (p<0.05) with ¹ paired t-tests to compare pre- and post- result; ² independent t-tests to compare NPF (natural porang flour) and SPF (*S. crispus* macerated porang flour). NPF6, NPF7 or SPF6, SPF7 were administered with the dose of 2000 and 5000 mg/kg BW, respectively.

As a confirmation test for the effect of oral administration of porang flour, this study also conducted a kidney histopathology test (Figure 2). Histopathology of the kidney showed that all renal organs changed in terms of anatomical pathology in the form of congestion, except for the NPF7 group which was in the form of hemorrhage. Mild congestion was found in the control, NPF6, and SPF6 groups, while the most severe congestion was seen in SPF7.

Congestion and hemorrhage in this study may be excluded from histopathological parameters, because it was included in a natural process that usually occurs after decapitation. Decapitation leads to tissue injury which causes an increase in blood flow to organs, one of which is the kidneys. In kidney congestion, there is an increase in venous blood pooling in the renal vascular that may be due to physiological conditions, passive blood pressure, and secondary effects to hypovolemic shock, insufficiency, and hypostatic cardiac. In this condition, capillary dilation occurs due to vasodilator stimulation so that the vascularization at the site of the injury widens and contains stagnant blood. Meanwhile, hemorrhage can occur due to the breakdown of blood vessels after congestion or intolerable congestion [32].

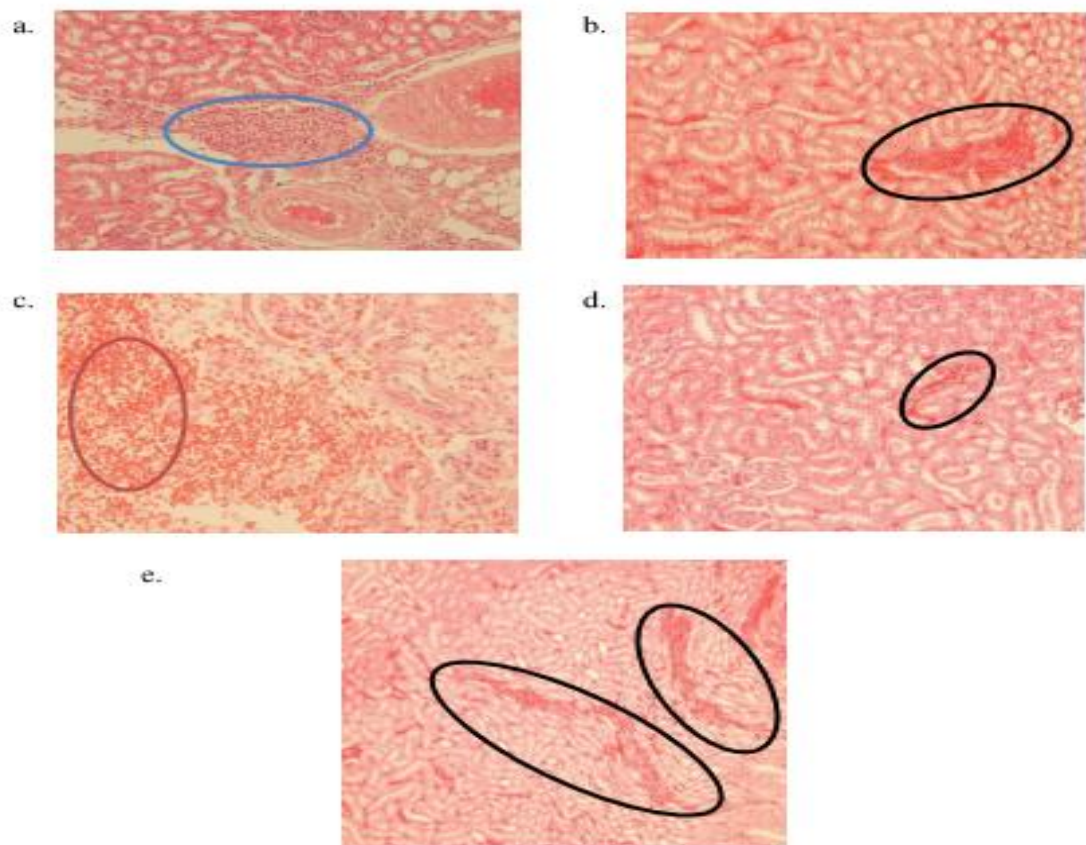


Figure 2: Histopathological examination of kidney organ of the rat in acute oral toxicity study of porang and *S. crispus* macerated porang flour: a) control group, b) NPF6, c) NPF7, d) SPF6, e) SPF7. Blue, red, and black circles describe inflammation, hemorrhage, and congestion, respectively

SGOT levels of blood serum

SGOT blood serum levels increased significantly in NPF7 and SPF7 groups, both in the observation of 24 h and 72 h after oral administration ($p < 0.05$) (Table 2). It meant that the high dose of porang and *S. crispus*-macerated porang flour had an impact on SGOT levels. However, the increase was still in the normal range between 36.99-42.62 U/L [33]. This study was in line with other subacute toxicity studies that used glucomannan flour with the dose of 4000 mg/kg BW and porang flour in acute toxicity study at a dose of 5000 mg/kg BW (21,17).

Table 2 also showed that there were no differences between NPF and SPF groups in the dose of 2000 and 5000 mg/kg BW. It indicated that *S. crispus* maceration did not affect the SGOT levels. The increase in SGOT levels affected by the calcium oxalate content which has the risk of damaging the liver cell membrane so that its permeability was impaired, resulting in the SGOT enzyme leaving cells freely, entered the extracellular space and blood vessels beyond normal conditions [23,35].

Table 2: SGOT blood serum levels of rats in acute toxicity study of porang and *S. crispus* macerated porang flour

SGOT (U/L)	NPF6 (mean±SD)	SPF6 (mean±SD)	NPF7 (mean±SD)	SPF7 (mean±SD)
24 h				
Pre	37.38 ± 0.77	37.67 ± 0.55	37.38 ± 0.34	36.61 ± 1.22
Post	37.58 ± 0.55	39.03 ± 0.74	45.54 ± 0.93	43.50 ± 0.55
P-value ¹	0.704	0.009*	0.000*	0.000*
Δ	0.19 ± 1.06	1.36 ± 0.63	8.16 ± 1.16	5.83 ± 0.97
P-value ²		0.068		0.158
72 h				
Pre	37.38 ± 0.77	37.67 ± 0.55	37.38 ± 0.34	36.61 ± 1.22
Post	37.67 ± 0.77	36.99 ± 1.34	42.14 ± 0.41	42.62 ± 0.63
P-value ¹	0.552	0.245	0.000*	0.001*
Δ	0.29 ± 1.01	-0.68 ± 1.12	4.76 ± 0.53	6.02 ± 1.63
P-value ²		0.189		0.138

*Significant ($p < 0.05$) with ¹ paired t-tests to compare pre- and post- result; ² independent t-tests to compare NPF (natural porang flour) and SPF (*S. crispus* macerated porang flour). NPF6, NPF7 or SPF6, SPF7 were administered with the dose of 2000 and 5000 mg/kg BW, respectively.

In addition, psychological factors occurred due to repeat blood sampling in a relatively short time, leading to stress which also triggered the release of the SGOT enzyme in the blood and increased SGOT levels [36]. Several studies proved that the increase of SGOT enzyme levels did not specifically indicate liver dysfunction, because the enzyme was also found in the skeletal muscles, pancreas, heart, blood vessels of the brain, lungs, and testes [37,38]. Thus, the increase in SGOT levels was not only caused by damage to the liver cells but also other organs.

SGPT levels of blood serum

SGPT levels of blood serum had a similar result to SGOT, which increased significantly after oral administration of porang in NPF7 and SPF7 groups ($p < 0.05$).

However, there was no significant difference between NPF6 and SPF6 groups ($p > 0.05$). These results explain that at higher doses (up to 5000 mg/kg BW), porang both with or without maceration affected the increase of SGPT.

SGPT levels in this study were classified as normal (18.16-24.96 U/L) [33]. However, an increase in SGPT needs attention, because it is an indicator of active hepatocellular damage [39]. Several studies conducted in France, North America, and the Pacific Islands had proven the occurrence of hepatitis in patients who consumed herbal ingredients in high doses for long period [40–42]. Therefore, it needs further studies to know the effects of consuming porang for a longer period on the liver. The tendency of SGPT to increase in this study could be caused by the content of needle-shaped calcium oxalate crystals that may dissolve in the blood and scratch or damage the liver cells. In addition, toxicity may occur as the interaction between components in porang containing calcium oxalate and *S. crispus* containing alkaloids, saponins, flavonoids, potassium, and polyphenols [43,44].

Table 3: SGPT blood serum levels of rats in acute toxicity study of porang and *S. crispus* macerated porang flour

SGPT (U/L)	NPF6 (mean±SD)	SPF6 (mean±SD)	NPF7 (mean±SD)	SPF7 (mean±SD)
24 h				
Pre	18.74 ± 0.26	18.45 ± 0.34	18.45 ± 0.59	18.06 ± 0.63
Post	18.16 ± 0.65	18.64 ± 0.43	24.96 ± 0.55	23.88 ± 0.41
P-value ¹	0.109	0.178	0.000*	0.000*
Δ	-0.58 ± 0.63	0.20 ± 0.27	6.51 ± 0.27	5.83 ± 0.97
P-value ²		0.035*		0.170
72 h				
Pre	18.74 ± 0.26	18.45 ± 0.34	18.45 ± 0.59	18.06 ± 0.63
Post	18.45 ± 0.34	18.35 ± 0.53	23.40 ± 0.40	23.40 ± 0.40
P-value ¹	0.209	0.800	0.000*	0.001*
Δ	-0.29 ± 0.43	-0.10 ± 0.80	4.95 ± 0.80	5.34 ± 0.49
P-value ²		0.643		0.378

*Significant ($p < 0.05$) with ¹ paired t-tests to compare pre- and post- result; ² independent t-tests to compare NPF (natural porang flour) and SPF (*S. crispus* macerated porang flour). NPF6, NPF7 or SPF6, SPF7 were administered with the dose of 2000 and 5000 mg/kg BW, respectively.

Conclusions

Based on the acute toxicity study, it can be concluded that porang and porang macerated with *S. crispus* were not toxic until the highest dose of 5000 mg/kg BW. It was proved by the absence of LD50, no change in behavior, no weight losses, and also the results of biochemical tests, such as urea protein, SGOT, and SGPT which were still in the normal range. It is necessary to carry out further toxicity studies, including sub chronic to determine the safety level of porang and *S. crispus* consumption for long period.

Acknowledgments

The authors would like to thank Alma Ata University for the many facilities for this study.

References

1. Koswara S. Teknologi pengolahan umbi-umbian. Bagian 2 : Pengolahan Umbi Porang. Bogor: SEAFast IPB; 2013.
2. Risti D, Aprilia V, Nisa FZ. Sifat fisik, kadar serat, dan daya terima naget dengan penggunaan glukomanan dari porang (*Amorphophallus oncophyllus*) untuk substitusi daging ayam. *J Gizi dan Diet Indones (Indonesian J Nutr Diet)*. 2018;5(1):9–16.
3. Faridah A, Bambang Widjanarko S. Penambahan tepung porang pada pembuatan mi dengan substitusi tepung mocaf (modified cassava flour). *J Teknol dan Ind Pangan [Internet]*. 2014;25(1):98–105. Available from: <http://journal.ipb.ac.id/index.php/jtip/article/view/8309>
4. Putri VN, Susilo B, Hendrawan Y. Pengaruh penambahan tepung porang (*Amorphophallus onchophyllus*) pada pembuatan es krim instan ditinjau dari kualitas fisik dan organoleptik. *J Keteknikan Pertan Trop dan Biosist*. 2014;2(3):188–97.
5. Vuksan V, Sievenpiper JL, Owen R, Swilley JA, Spadafora P, Jenkins DJA, et al. Beneficial effects of viscous dietary fiber from Konjac-Mannan in subjects with the insulin resistance syndrome: Results of a controlled metabolic trial. *Diabetes Care*. 2000;23(1):9–14.
6. Lukitaningsih E, Rumiati, Puspitasari I. Kajian Glikemik Indeks dan Makronutrien dari Umbi-Umbian dalam Upaya Pencarian Sumber Pangan Fungsional. *Pharmacon*. 2012;13(1):18–23.
7. Chen H, Nie Q, Hu J, Huang X, Zhang K, Pan S, et al. Hypoglycemic and Hypolipidemic Effects of Glucomannan Extracted from Konjac on Type 2 Diabetic Rats. *J Agric Food Chem*. 2019;67(18):5278–88.
8. Zheng J, Li H, Zhang X, Jiang M, Luo C, Lu Z, et al. Prebiotic Mannan-Oligosaccharides Augment the Hypoglycemic Effects of Metformin in Correlation with Modulating Gut Microbiota. *J Agric Food Chem*. 2018;66(23):5821–31.
9. Ernawati E, Aprilia V, Pangastuti R. The increase of blood creatinine levels and the gastric histopathology of rat after feeding of porang (*Amorphophallus oncophyllus*) flour treated with *Strobilantehes crispa*. *Indones J Nutr Diet*. 2018;6(3):113–21.
10. Pramathana A. Karakteristik tepung porang (*Amorphophallus oncophyllus*)

- dengan variasi perendaman abu dan garam dapur dalam rangka pengurangan kandungan asam oksalat. Universitas Jember; 2013.
11. Mawarni RT, Widjanarko SB. Penggilingan metode ball mill dengan pemurnian kimia terhadap penurunan oksalat tepung porang. *J Pangan dan Agroindustri*. 2015;3(2):571–81.
 12. Sanjaya MITF, Kunarto B, Wahjuningsih SB. Kombinasi lama perendaman dalam natrium klorida dan ukuran partikel (mesh) terhadap glukomanan, kalsium oksalat dan serat makan tepung umbi porang (. *J Teknol Pangan dan Has Pertan*. 2012;9(2):16–23.
 13. Astuti RD, Prastowo A, Aprilia V. Porang fl our (*Amorphophallus oncophyllus*) with and without soaking of keji beling extract increases the value of ureum on toxicity test in wistar rat (*Rattus norvegicus*). *Indones J Nutr Diet*. 2017;5(3):93–7.
 14. Noonan SC. Oxalate content of foods and its effect on humans. *Asia Pac J Clin Nutr*. 1999;8(1):64–74.
 15. Faridah A, Widjanarko SB, Sutrisno A, Susilo B. Optimasi produksi tepung porang dari chip porang secara mekanis dengan metode permukaan respons. *J Tek Ind*. 2012;13.
 16. Saputro EA, Lefiyanti O. Pemurnian tepung glukomanan dari umbi porang (*Amorphophallus muelleri* Blume) menggunakan proses ekstraksi/leaching dengan larutan etanol. In: *Simposium Nasional RAPI XIII*. Solo: Fakultas TEknik Universitas Muhammadiyah Surakarta; 2014. p. 7–13.
 17. Yuswardani DK, Nida S, Fadilah. Penggunaan tawas ($Al_2(SO_4)_3$) dalam pemurnian glukomannan dari umbi poang (*Amorphophallus muelleri* Blume) sebagai bahan baku hydrogel untuk penghantaran obat. In: *Simposium Nasional RAPI*. Solo: Universitas Muhammadiyah Surakarta; 2014. p. 21–8.
 18. Dewi MS. Mempelajari Daya Larut Kalsium Oksalat Oleh Ekstrak dan Fraksi Air Daun Kejibeling (*Strobilanthes crispus*). Universitas Andalas; 2009.
 19. Aprilia V, Nurinda E, Alpina L, Hadi H, Ariftiyana S, Kurniasari Y. Proses reduksi kalsium oksalat pada tepung porang (*Amorphophallus oncophyllus*) dengan maserasi ekstrak daun keji beling (*Strobilanthes crisp*a) [Internet]. Indonesia; S00202006668, 2020. Available from: <https://pdki-indonesia.dgip.go.id/detail/S00202006668?type=patent&keyword=proses+reduksi+kalsium+oksalat>
 20. BPOM RI. Peraturan Kepala Badan Pengawas Obat dan Makanan Republik Indonesia Nomor 7 Tahun 2014 Tentang Pedoman Uji Toksisitas Non Klinik Secara In Vivo. 2014.
 21. Price, S. A., dan Wilson LM. Patofisiologi Ginjal. In: *Patofisiologi Konsep Klinis*

- Proses-Proses Penyakit. Jakarta: Buku Kedokteran EGC; 1995. p. 769–71, 795–7.
22. Krysanti A, Widjanarko SB. Subacute Toxicity Testing of Glucomannan (*A . muelleri* Blume) Toward SGOT and Sodium of Wistar Rats by In Vivo. *J Pangan dan Agroindustri*. 2014;2(1):1–6.
 23. Natalia ED, Widjanarko SB, Ningtyas DW. Acute Toxicity Test Of Glucomannan Flour (*A . muelleri* Blume) Toward Potassium Of Wistar Rats. *J Pangan dan Agroindustri*. 2014;2(1):132–6.
 24. OECD. OECD Guidelines for Testing og Chemicals. Test No. 420: Acute Oral Toxicity – Fixed Dose Procedure (chptr). 2001;(December):1–14.
 25. Hodge A, Sterner B. Toxicity Classes. In: Canadian Center for Occupational Health and Safety; 2005.
 26. Mundt, L. dan Shanahan K. Graff’s Textbook of Urinalysis and Body Fluids. Kluwer W, editor. Philadhelpia; 2010.
 27. Harris, P., Mann, L., Phillips, B., Webster C. Diabetes management in general practice gideline for type 2 diabetes. Australia: Diabetes Australia; 2011.
 28. Wicaksono MA. Evaluasi Fungsi Hati dan Gibjal Tikus Betina (*Rattus norvegicus*) galur Sprague-Dawley pada pemberian jamu Galohgor. Bogor Agricultural University; 2010.
 29. Korth KL, Doege SJ, Park S-H, Goggin FL, Wang Q, Gomez SK, et al. Medicago truncatula mutants demonstrate the role of plant calcium oxalate crystals as an effective defense against chewing insects. *Plant Physiol*. 2006;141(1):188–95.
 30. Keppel, J., Calissi P. Safe Drug Prescribing for Patients with Renal Insufficiency. *Can Med Assoc J*. 2002;166(6):473–7.
 31. Albright Jr RC. Acute Renal Failure: A Practical Update. *Mayo Clin Proc*. 2001;76:67–74.
 32. Arimbi. Buku Ajar Patologi Veteriner : Respon Sel dan Jaringan Terhadap Jejas serta Gangguan Hemodinamik. Fakultas Kedokteran Hewan Universitas Airlangga. Surabaya. 2010. 13–83 p.
 33. Mitruka BM. Clinical Biochemical and Hematological Reference Values in Normal Experimental Animals and Normal Humans. 2nd ed. Chicago: Masson Publishing; 1981.
 34. Donowarti I, Widjanarko SB, Yunianta Y, Pudjiastuti P. Acute toxicity test of low calcium oxalate porang (*Amorphophallus muelleri* Blume) flour. *Iraqi J Agric Sci*. 2021;52(1):218–31.
 35. Fathoni F. Studi Kasus SGPT, SGOT, dan Total Protein pada Serum Darah

- Anjing Kampung (*Canis familiaris*) Usia 3 Bulan dan 6 Bulan. IPB: Bogor; 2008.
36. Ardiani F. Pengaruh Pemberian Ekstrak Air Ceplikan (*Reullia Tuberosa* L) Terhadap Kadar SGOT dan SGPT serta Gambaran Histologis Hepar pada Tikus Putih (*Rattus Norvegicus*) Diabetes Mellitus. UGM; 2008.
 37. Loeb, W. F., Quimbly FW. *The Clinical Chemistry of Laboratory Animals*. London: Pergamon Press Inc; 1989.
 38. Hadi S. *Gastroenterologi*. Bandung: Alumni; 1986.
 39. Baron DN. *Kapita Selekta Patologi Klinik*. 4th ed. Jakarta: EGC; 1990.
 40. Shad, J. A., Brann OS. Acute Hepatitis After Ingestion of Herbs. *South Med J*. 1999;92(11):1095–7.
 41. Laliberte, L., Villeneuve JP. Hepatitis After The Use of Germander, A Herbal Remedy. *Can Med Assoc J*. 1996;154(11):1689–92.
 42. Currie, B. J., Clough AR. Kava Hepatotoxicity With Western Herbal Products: Does It Occur With Traditional Kava Use? *Med J Aust*. 2003;178:421–2.
 43. Widowati L, Winarno MW, Intan PR, Teknologi P, Kesehatan T. Toksisitas Akut dan Subkronis Ramuan Ekstrak Kelor dan Klabet sebagai Pelancar ASI dan Penambah Gizi. *J Kefarmasian Indones*. 2014;4(2):51–63.
 44. Adiwisastra A. *Keracunan: Sumber, bahaya, serta penanggulangannya*. Bandung: Angkasa; 1985.

6813 / A'yun et al. / Acute Toxicity Study of Porang (*Amorphophallus oncophyllus*) Flour Macerated with *Strobilanthes crispus* in Wistar Rats

Library

Workflow Publication

Submission Review Copyediting Production

Round 1

Round 1 Status

Submission accepted.

Notifications

[QAMJMS] Editor Decision	2021-08-18 11:12 PM
[QAMJMS] Editor Decision	2021-09-15 01:55 AM
[QAMJMS] Editor Decision	2021-11-02 04:56 AM

[https://oamims.eu/index.php/mims/\\$\\$\\$\\$call\\$\\$\\$/tab/author-dashboard/author-dashboard-tab/fetch-tab?submissionId=6813&stageId=3](https://oamims.eu/index.php/mims/$$$$call$$$/tab/author-dashboard/author-dashboard-tab/fetch-tab?submissionId=6813&stageId=3)

Q Search

Rizka Qurrota A'yun, Uswatun Hasanah, Hamam Hadi, Mustofa, Eva Nurinda, Yulinda Kurniasari, Veriani Aprilia (Author):

We have reached a decision regarding your submission to Open Access Macedonian Journal of Medical Sciences, "An Acute Toxicity Study of Porang (*Amorphophallus oncophyllus*) Flour Macerated with *Strobilanthes crispus* in Wistar Rats ", Manuscript ID = OJS6813.

Our decision is: Revise your manuscript until September 15, 2021 and submit on the OAMJMS website.

Sincerely,
Prof. Dr Mirko Spiroski,
Editor-in-Chief, OAMJMS

Reviewer B:
Recommendation: Accept Submission

Reviewer C:
Recommendation: Decline Submission

Reviewer D:
Recommendation: Revisions Required

Reviewer E:

The manuscript is well written and presented. Having read the manuscript, I have the following comments:

1. For the main study of NPF6, NPF7, SPF6, and SPF7 please provide the additional study results of body weight. Does it affect the body weight of the animals with those high doses?
2. On page 6 paragraph 1, the authors declared to exclude the congestion and hemorrhage, but in figure 2, authors include these parameters. Authors should be consistent in making a statement that represents the results.
3. Please add the scale bar in Figure 2.
4. If possible, please provide a picture/arrow of calcium oxalate formation in the kidney. It is very possible that the calcium oxalate will be accumulated due to a significantly increased level of calcium oxalate in the body.

Recommendation: Revisions Required

RESPONSES THE REVIEWER'S COMMENTS

Manuscript ID: OJS6813

Title: An Acute Toxicity Study of Porang (*Amorphophallus oncophyllus*) Flour Macerated with *Strobilanthes crispus* in Wistar Rats

Reviewer D

No.	Referee's Comments	Responses (for author)
1.	It is necessary to explain why using female rats as experimental animals	Female rats were used because they were more sensitive than male rats (It has been added on Page 2) line 38
2.	Bibliography needs improvement	It has been revised, page 10.

Reviewer E

No.	Referee's Comments	Responses (for author)
1.	For the main study of NPF6, NPF7, SPF6, and SPF7 please provide the additional study results of body weight. Does it affect the body weight of the animals with those high doses?	<p>We have published the bodyweight of rats in main study in the previous paper (reference number 10) (the paper was also attached). We also have mentioned it in a sentence (page 4, line 8). The main study body weight showed no difference between both natural porang flour and macerated-porang flour at high doses (2000 mg/kg BW and 5000 mg/kg BW).</p> <p>To strengthen the answer whether there was the effect of porang administration on bodyweight of rats, we also showed our additional study (Figure 1B page 5). The current study was different in frequency of porang administration. In main study of toxicity study, the administration of porang was only once at the beginning, while in this additional study, porang was administered once/day during 3 days. The current study showed that there was the increase of body weight in all treatments with the similar rates (almost no differences), those were about 5-6 g. It can be concluded that there was not the effect of high dose of porang administration on the bodyweight of rats.</p>
2.	On page 6 paragraph 1, the authors declared to exclude the congestion and hemorrhage, but in figure 2, authors include these parameters. Authors should be consistent in making a statement that represents the results.	Thank you for your correction. We have revised our statement that can be seen in page 7, line 12.

3.	Please add the scale bar in Figure 2	We apologize for not adding the scale bar in Figure 2 (page 8, line 3), but we have completed the magnification of microscope, that was 400x.
4.	If possible, please provide a picture/arrow of calcium oxalate formation in the kidney. It is very possible that the calcium oxalate will be accumulated due to a significantly increased level of calcium oxalate in the body.	Thank you for the suggestion. We try to inserting the calcium oxalate mechanism in the text that shown in page 6, line 26

1 Acute Toxicity Study of Porang (*Amorphophallus oncophyllus*) Flour 2 Macerated with *Strobilanthes crispus* in Wistar Rats

3 4 Abstract

5 **BACKGROUND:** Porang (*Amorphophallus oncophyllus*) is a local tuber food that high
6 in bioactive compound glucomannan. Its uses are limited due to oxalate acid content which
7 poses health risks. *Strobilanthes crispus* leaves could reduce the level of calcium oxalate
8 in porang. However, there is still no study to prove its safety.

9 **AIMS:** This study aimed to investigate the acute oral toxicity study of porang
10 (*Amorphophallus oncophyllus*) macerated with *Strobilanthes crispus* based on
11 observation of mortality rate (LD50), the changes in behavior during 72 h, renal and
12 hepatic function such as urinary protein, SGOT, and SGPT levels of Wistar rat (*Rattus*
13 *norvegicus*)

14 **METHODS:** An acute toxicity test was conducted based on the OECD 420 Fixed-Dose
15 Procedure Guideline that consists of preliminary and main studies. For the preliminary
16 study, rats were divided into control and 5 treatment groups with the dosage of 50, 300,
17 2000, 5000 mg/kg bodyweight (BW) for each natural porang flour/NPF and *S. crispus*-
18 macerated porang flour/SPF. For the main study, rats were divided into 4 groups, those
19 were NPF and SPF with the dosage of 2000 and 5000 mg/kg BW. Levels of urinary
20 protein and blood serum SGOT and SGPT levels were measured at 0, 24, and 72 after
21 treatment.

22 **RESULTS:** The acute toxicity study showed that porang and porang macerated with *S.*
23 *crispus* were not toxic until the highest dose of 5000 mg/kg BW. It was proved by the
24 absence of LD50, no change in behavior, no weight losses, and also the results of
25 biochemical tests, such as urinary protein, SGOT, and SGPT which were still in the
26 normal range.

27 **CONCLUSION:** Porang flour and *S.crispus*-macerated porang flour were concluded as
28 non-toxic food based on acute toxicity study.
29

30 **Keywords:** *Amorphophallus oncophyllus*, *Strobilanthes crispus*, LD50, urinary protein,
31 SGOT, SGPT

32 33 Introduction

34 Porang or iles-iles is included in the genus of *Amorphophallus*. These plants wildly
35 grow in the jungle, under the bamboo tree, along the riverside, and mountain slope [1].
36 Porang tuber (*Amorphophallus oncophyllus*) contains glucomannan or known as mannan.
37 Glucomannan is a water-dissolved food fiber that is low in calories and has a special
38 function for diet, so that it has been widely used for food products [2]. The food
39 containing glucomannan reduced cholesterol level, blood sugar, and hypertension [3]. Its
40 relatively low glycemic index could decrease blood sugar level and made this tuber was
41 good to be consumed by diabetic patients. It proved to boost the therapy of diabetes type

1 2 through lipid metabolism improvement [4], while other study reported that
2 glucomannan worked in synergy with metformin to increase its hypoglycemia effect [5].

3 Even though it had been proven that there were many benefits of glucomannan, the
4 utilization of porang tuber as the source of glucomannan is still low. This is caused by the
5 homemade product of porang still has the weakness, that is itchy when consumed. This
6 itchiness is caused by the content of oxalate [6–9]. Oxalate acid consumption in a high
7 number increased blood creatinine and urea levels [6,10]. It also decreased the
8 bioavailability of calcium inside the body, formed kidney stones, can cause corrosion of
9 the mouth and gastrointestinal tract, kidney failure, and hematuria [11].

10 Various efforts had been carried out to reduce the level of calcium oxalate level in
11 porang tuber, both mechanically using stamp mill and blower, ball mill, also chemically
12 using NaCl [8,9,12]. The research using natural or herbal ingredients in reducing oxalate
13 calcium content is still limited. In a previous study, ethanol extract of *Strobilanthes*
14 *crispus* leaves reduced the level of calcium oxalate in porang flour [13], but it still needs
15 to be proved before consumption for its safety. Therefore, in vivo toxicity test is needed
16 to be carried out.

17 A toxicity test is a set of analyses to detect the toxic effect of a substance on the
18 biological system and to obtain typical dose-response data from the test preparation [14].
19 In addition, a toxicity test can be carried out to determine the toxic effects on the vital
20 organs of the animal, such as the kidneys and liver. One of the kidney functions is to
21 excrete foreign compounds such as drugs, food, pesticides, and other non-nutritional
22 exogenous materials that enter the body [15]. The study of the level of porang toxicity
23 was reported on porang tubers [16,17], but its combination with *S. crispus* needs to be
24 studied further.

25 In this study, an acute toxicity test was conducted by observing the mortality rate
26 (LD50) and the changes in behavior during 72 h. To confirm the kidney and liver function,
27 the urea protein tests, kidney histopathology, and biochemical tests of aminotransferase
28 enzyme activity (SGOT and SGPT) were also done.

30 **Materials and methods**

31 **Plant materials and sample preparation**

32 Porang was purchased from the farmer in Madiun, East Java. It was directly
33 processed into flour at the laboratory. Porang flour macerated with *S. crispus* was then
34 produced based on the Patent Application No. S00202006668 [18].

36 **Experimental animals**

37 Non-pregnant female Wistar (*Rattus Norvegicus*) rats weighing 110-180 g with the
38 age of 8-12 weeks were used in this acute study. Female rats were used because they were
39 more sensitive than male rats [14]. For the preliminary study, eleven rats were used. Each
40 of them was represented as a treatment group based on the dose of oral feeding, i.e. control
41 (distilled water treatment), NPF1 (natural porang flour), NPF2, NPF3, NPF4, NPF5, and
42 SPF1 ((*S. crispus*-macerated porang flour), SPF2, SPF3, SPF4, SPF5 for) for the dose of

1 50, 300, 2000, 5000 mg/kg of bodyweight (BW), respectively. For the main study, twenty
2 rats were divided into 4 groups, i.e. NPF6 (dose of 2000 mg/kg BW), NPF7, SPF6, ad
3 SPF7.

4 An acute toxicity study was conducted based on the Organization of Economic Co-
5 Operation and Development (OECD) Guideline 420 for testing chemicals. The
6 procedures consisted of two steps, those were preliminary and main analysis. For
7 preliminary analysis, the rats were orally administered with porang flour or *S. crispus*-
8 macerated porang flour with doses of 5, 50, 300 mg/kg BW. If there was no mortality, the
9 dose was increased up to 2000 mg/kg BW. For the main analysis, the doses used were
10 2000 mg/kg BW and 5000 mg/kg BW [19].

11 The acclimatization of animals was 5 d and fed with free access to standard
12 laboratory diet and ad-libitum water. They were then fasted for 18 h before administered
13 with the flours. The mortality, any injury or illness, physical appearance, behavior
14 changes (step backward, walk with the stomach, sleepy), diarrhea were observed visually
15 after the first 30 min and every 1 h for 24 h. If there was no sign of toxicity, the test was
16 completed until 72 h. The bodyweight of rats was monitored at the beginning and the end
17 of the analysis. The urine and blood samples were collected before treatment, 24 h and
18 72 h after treatment for determining the urinary protein levels, SGOT (serum glutamic
19 oxaloacetic transaminase), and SGPT (serum glutamic pyruvic transaminase) levels,
20 respectively. At the end of the study, rats were euthanized by decapitation, the kidney
21 organs were excised carefully, then preserved in 10% buffered formalin before the
22 histopathological study.

23 Urinary protein levels were analyzed by the pyrogallol red-molybdate method.
24 SGOT and SGPT were analyzed by Optimized UV-test according to IFCC (International
25 Federation of. Clinical Chemistry and Laboratory Medicine) [14].

26 27 **Statistical analysis**

28 Data were performed by mean values, followed by statistical analysis used SPSS ver.
29 16. The differences between samples were tested by analysis of variance (ANOVA) with
30 Duncan's multiple range test. Differences were significant when $p < 0.05$.

31 32 **Results and discussion**

33 **Acute oral toxicity study**

34 The first acute oral toxicity study was preliminary. This study was important to find
35 the starting dose that must be done in the main study because there was still no study
36 about the toxicity of porang with the combination of *S. crispus*. The study showed that
37 there was no mortality (LD50), injury, physical appearance, or behavior changes from the
38 first 30 min until 72 h observations, for both NPF and SPF groups. The data were used as
39 the reason to conduct the main study with the dose of 2000 mg/kg BW and 5000 mg/kg
40 BW.

41 The main study was also showed no toxicity sign and mortality in all groups. Because
42 the maximum dose did not cause mortality, LD50 was stated as apparent LD50. Based on

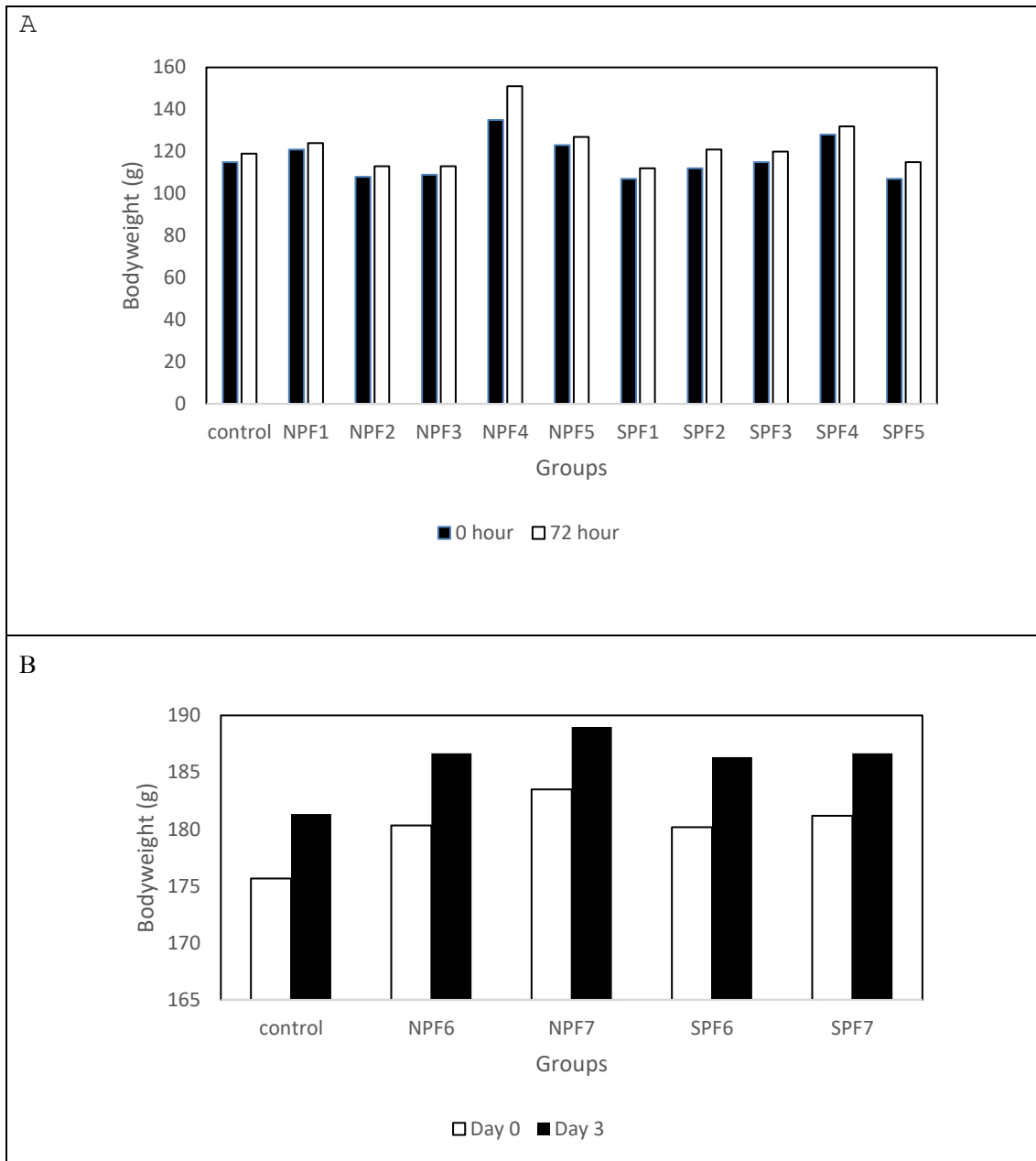
1 The Hodge and Sterner Toxicity Scale, porang both natural and macerated with *S. crispus*
2 were categorized as practically non-toxic due to no mortality (LD50) at the administration
3 dose of 5000-15000 mg/kg BW [20].
4

5 **Bodyweight of rats**

6 Figure 1A showed the bodyweight of rats during 72 h of preliminary study. The
7 bodyweight of rats in this preliminary test did not show the weight loss that was in line
8 with the results of the main study [10]. For this acute oral toxicity study, the
9 administration of porang flour was once in the beginning of study and the body weight
10 were measured at the beginning and the end of study. The additional study with the
11 administration of high doses porang (NPF6, NPF7, SPF6, SPF7) and control with the
12 frequency of once/day during 3 days was also conducted (Figure 1B). It was done to
13 strengthen the answer whether there was the effect of porang administration on
14 bodyweight of rats. The data showed that there was the increase of body weight in all
15 treatments with the similar rates, those were about 5-6 g.

16 This data showed that there was no absence of weight loss during administration of
17 porang. It indicated that their growth was normal or there was no indication of impaired
18 absorption of nutrients due to the oral administration of porang flour both natural and
19 macerated with *S. crispus*.
20
21
22
23
24
25
26
27
28
29
30
31
32
33
34
35
36
37
38
39
40
41
42
43

1



2
3
4
5
6
7
8
9
10

Figure 1: Bodyweight of rats in acute toxicity study of natural porang and *S. crispus*-macerated porang flour A) with the administration only at the beginning of preliminary study (control=distilled water treatment, NPF=natural porang flour, SPF= *S. crispus*-macerated porang flour. NPF1, NPF2, NPF3, NPF4, NPF5 and SPF1, SPF2, SPF3, SPF4, SPF5, for the dose of 50, 300, 2000, 5000 mg/kg BW, respectively); B) with the administration of once/day during 3 days of study (control=distilled water treatment, NPF6, NPF7, and SPF6, SPF7 for the dose of 2000 and 5000 mg/kg BW, respectively)

Urinary protein levels and histopathological examination of kidney organ

The effect of the administration of porang flour on urinary protein levels was shown in Table 1. All groups showed urinary levels under 200 mg/L that categorized as normal levels [21]. However, there was an increase observed in NPF7 and SPF7 both in 24 h and 72 h of administration and NPF6 after 72 h of administration ($p < 0.05$). It indicated that the elevation of protein levels may be seen at a shorter time when a higher dose was applied.

The increase of protein levels in the urine indicated a progression to a reduction in renal performance [22]. This study was relevant to the previous publication of the same study which showed an increase in urea and creatinine levels which can be used as an indicator of kidney function/performance [6,10]. In another study, the administration of the herbal medicine of galohgor also showed an increase in urea level, creatinine, and urinary protein [23]. In this study, the decrease was still within the normal range, therefore it is necessary to confirm with further toxicity tests of sub chronic and others to find out whether in a longer period of studies there will be a gradual reduction in kidney performance.

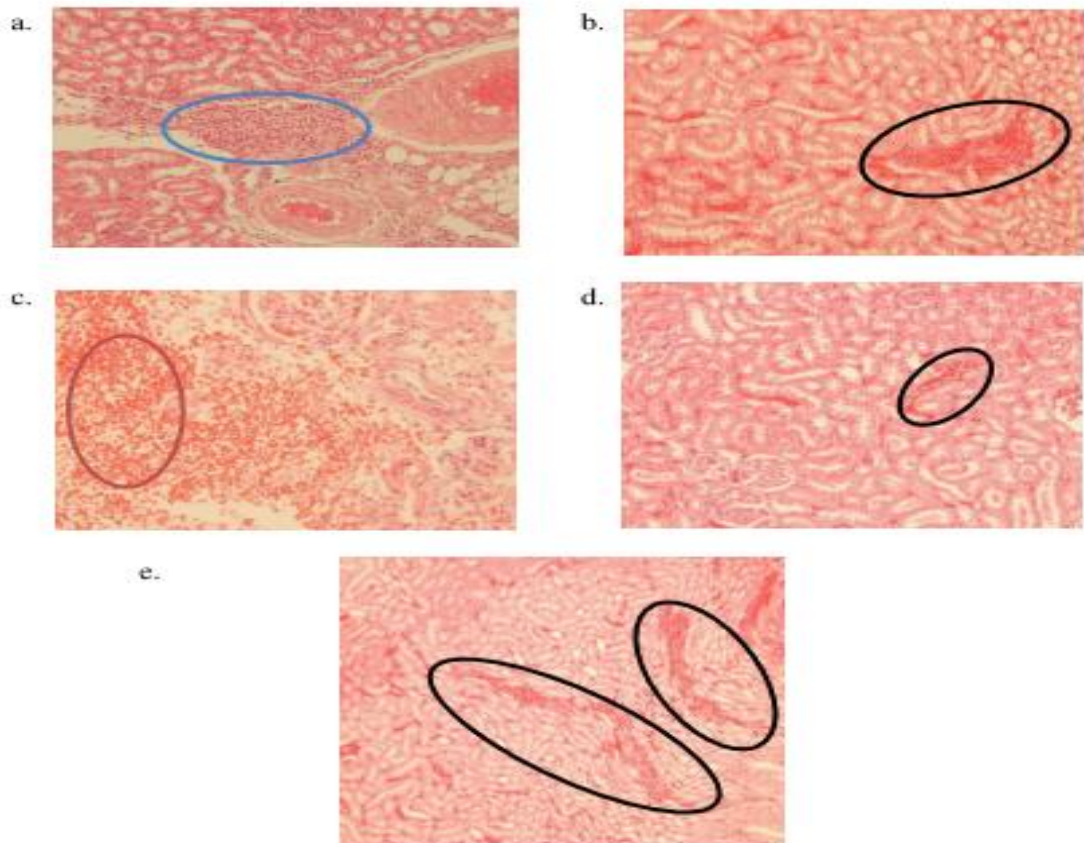
In this study, there was no difference in urea protein levels between the NPF and SPF groups, which indicated that immersion in *S. crispus*, which is one of the herbal medicines, did not affect increasing urea protein levels. However, porang flour contains components that can cause the risk of damage to the kidneys, namely calcium oxalate. Calcium oxalate had an impact on mechanical abrasion of the gastrointestinal tract and renal smooth tubules [24]. In another study, the administration of herbal medicine caused acute tubular necrosis or fibrotic interstitial nephritis that occurred rapidly and progressively. This syndrome was characterized by progressive renal failure, the discovery of a lot of urine sediment, shrinkage of kidney size with mild proteinuria, and was associated with the incidence of urothelial cancer [25,26]. Calcium oxalate may also form the kidney stone that the incidence is rising recently with the lifetime risk of 10-15% [27]. This clinical stone formation begins from the nucleation of crystal either in supersaturated renal tubular fluid or in the renal interstitial fluid. This may be influenced by the rising of stone component molecules, the lowering of urine volume, the changing of pH, or the combining of these factors. The crystal may growth in size that may combine with some intrarenal structure and further nucleation to generate the stone [28].

Table 1: Urinary protein levels of rats in acute toxicity study of porang and *S. crispus* macerated porang flour

Urinary Protein (mg/L)	NPF6 (mean±SD)	SPF6 (mean±SD)	NPF7 (mean±SD)	SPF7 (mean±SD)
24 h				
Pre	62.32 ± 7.23	59.45 ± 4.78	60.33 ± 6.03	60.33 ± 2.29
Post	62.74 ± 6.83	59.29 ± 3.90	77.77 ± 2.11	74.92 ± 4.73
P-value ¹	0.235	0.783	0.004*	0.005*
Δ	0.42 ± 0.68	-0.16 ± 1.18	17.43 ± 6.68	14.59 ± 5.68
P-value ²	0.370		0.489	
72 h				
Pre	62.32 ± 7.23	59.45 ± 4.78	60.33 ± 6.03	60.33 ± 0.29
Post	65.91 ± 5.60	60.13 ± 4.21	80.50 ± 1.99	76.48 ± 5.21
P-value ¹	0.009*	0.217	0.002*	0.005*
Δ	3.59 ± 1.68	0.68 ± 1.04	20.17 ± 6.41	16.15 ± 6.30
P-value ²	0,011*		0.346	

*Significant (p<0.05) with ¹ paired t-tests to compare pre- and post- result; ² independent t-tests to compare NPF (natural porang flour) and SPF (*S. crispus* macerated porang flour). NPF6, NPF7 or SPF6, SPF7 were administered with the dose of 2000 and 5000 mg/kg BW, respectively.

As a confirmation test for the effect of oral administration of porang flour, this study also conducted a kidney histopathology test (Figure 2). Histopathology of the kidney showed that all renal organs changed in terms of anatomical pathology in the form of congestion, except for the NPF7 group which was in the form of hemorrhage. Mild congestion was found in the control, NPF6, and SPF6 groups, while the most severe congestion was seen in SPF7. Congestion and hemorrhage were a natural process that usually occurs after decapitation. Decapitation leads to tissue injury which causes an increase in blood flow to organs, one of which is the kidneys. In kidney congestion, there is an increase in venous blood pooling in the renal vascular that may be due to physiological conditions, passive blood pressure, and secondary effects to hypovolemic shock, insufficiency, and hypostatic cardiac. In this condition, capillary dilation occurs due to vasodilator stimulation so that the vascularization at the site of the injury widens and contains stagnant blood. Meanwhile, hemorrhage can occur due to the breakdown of blood vessels after congestion or intolerable congestion.



1
2 **Figure 2: Histopathological examination of kidney organ of the rat in acute oral toxicity study of**
3 **porang and *S. crispus* macerated porang flour (magnification 400x): a) control group, b) NPF6, c)**
4 **NPF7, d) SPF6, e) SPF7. Blue, red, and black circles describe inflammation, hemorrhage, and**
5 **congestion, respectively**
6

7 **SGOT levels of blood serum**

8 SGOT blood serum levels increased significantly in NPF7 and SPF7 groups, both in
9 the observation of 24 h and 72 h after oral administration ($p < 0.05$) (Table 2). It meant
10 that the high dose of porang and *S. crispus*-macerated porang flour had an impact on
11 SGOT levels. However, the increase was still in the normal range between 36.99-42.62
12 U/L [29]. This study was in line with other subacute toxicity studies that used
13 glucomannan flour with the dose of 4000 mg/kg BW and porang flour in acute toxicity
14 study at a dose of 5000 mg/kg BW (21,17).

15 Table 2 also showed that there were no differences between NPF and SPF groups in
16 the dose of 2000 and 5000 mg/kg BW. It indicated that *S. crispus* maceration did not
17 affect the SGOT levels. The increase in SGOT levels affected by the calcium oxalate
18 content which has the risk of damaging the liver cell membrane so that its permeability

Reviewer's Attachments

Q Search

47471	veriani-aprilia-manuscript-main-text-macedonian-journal-of-medical-science.docx	July 27, 2021
-------	---	---------------

Revisions

Q Search

Upload File

▶ 52361	revisi_1_veriani-aprilia-manuscript-main-text-macedonian-journal-of-medical-science.docx	September 14, 2021	Revised Manuscript
▶ 52362	response to the reviewer_1.docx	September 14, 2021	Comments on the reviewers

Review Discussions

Add discussion

Name	From	Last Reply	Replies	Closed
▶ The identification of reviewer	vaprilia 2021-09-14 02:06 PM	-	0	<input type="checkbox"/>
[OAMJMS] Regular Publication Fee	admin 2021-10-10 01:03 AM	vaprilia 2021-10-15 01:17 AM	1	<input type="checkbox"/>
▶ Payment of publication fee	vaprilia 2021-11-01 12:05 PM	-	0	<input type="checkbox"/>

PRODUCTION

Open Access Macedonian Journal of Medical Sciences

← Back to Submissions

6813 / A'yun et al. / Acute Toxicity Study of Porang (Amorphophallus oncophyllus) Flour Macerated with Strobilanthes crispus in Wista Library

Workflow **Publication**

Submission Review Copyediting **Production**

Production Discussions Add discussion

Name	From	Last Reply	Replies	Closed
[QAM]MS] Proofreading Request (Author)	tfildishevska 2021-11-02 04:56 AM	-	0	<input type="checkbox"/>
▸ Corrected Galley Proof	vaprilia 2021-11-12 03:14 PM	-	0	<input type="checkbox"/>
▸ Corrected Galley Proof	vaprilia 2021-11-12 03:21 PM	-	0	<input type="checkbox"/>
▸ progress of the article	vaprilia 2021-12-21 06:05 PM	tfildishevska 2021-12-22 02:59 AM	1	<input type="checkbox"/>
[QAM]MS] Your Article was Published	ivos 2021-12-24 03:24 AM	-	0	<input type="checkbox"/>

was impaired, resulting in the SGOT enzyme leaving cells freely, entered the extracellular space and blood vessels beyond normal conditions [17].

Table 2: SGOT blood serum levels of rats in acute toxicity study of porang and *S. crispus* macerated porang flour

SGOT (U/L)	NPF6 (mean±SD)	SPF6 (mean±SD)	NPF7 (mean±SD)	SPF7 (mean±SD)
24 h				
Pre	37.38 ± 0.77	37.67 ± 0.55	37.38 ± 0.34	36.61 ± 1.22
Post	37.58 ± 0.55	39.03 ± 0.74	45.54 ± 0.93	43.50 ± 0.55
P-value ¹	0.704	0.009*	0.000*	0.000*
Δ	0.19 ± 1.06	1.36 ± 0.63	8.16 ± 1.16	5.83 ± 0.97
P-value ²		0.068		0.158
72 h				
Pre	37.38 ± 0.77	37.67 ± 0.55	37.38 ± 0.34	36.61 ± 1.22
Post	37.67 ± 0.77	36.99 ± 1.34	42.14 ± 0.41	42.62 ± 0.63
P-value ¹	0.552	0.245	0.000*	0.001*
Δ	0.29 ± 1.01	-0.68 ± 1.12	4.76 ± 0.53	6.02 ± 1.63
P-value ²		0.189		0.138

*Significant (p<0.05) with ¹ paired t-tests to compare pre- and post- result; ² independent t-tests to compare NPF (natural porang flour) and SPF (*S. crispus* macerated porang flour). NPF6, NPF7 or SPF6, SPF7 were administered with the dose of 2000 and 5000 mg/kg BW, respectively.

In addition, psychological factors occurred due to repeat blood sampling in a relatively short time, leading to stress which also triggered the release of the SGOT enzyme in the blood and increased SGOT levels. Several studies proved that the increase of SGOT enzyme levels did not specifically indicate liver dysfunction, because the enzyme was also found in the skeletal muscles, pancreas, heart, blood vessels of the brain, lungs, and testes [31]. Thus, the increase in SGOT levels was not only caused by damage to the liver cells but also other organs.

SGPT levels of blood serum

SGPT levels of blood serum had a similar result to SGOT, which increased significantly after oral administration of porang in NPF7 and SPF7 groups (p<0.05). However, there was no significant difference between NPF6 and SPF6 groups (p>0.05). These results explain that at higher doses (up to 5000 mg/kg BW), porang both with or without maceration affected the increase of SGPT.

SGPT levels in this study were classified as normal (18.16-24.96 U/L) [29]. However, an increase in SGPT needs attention, because it is an indicator of active hepatocellular damage. Several studies conducted in France, North America, and the Pacific Islands had proven the occurrence of hepatitis in patients who consumed herbal ingredients in high doses for long period [32–34]. Therefore, it needs further studies to know the effects of consuming porang for a longer period on the liver. The tendency of SGPT to increase in this study could be caused by the content of needle-shaped calcium oxalate crystals that may dissolve in the blood and scratch or damage the liver cells. In addition, toxicity may be occurred as the interaction between components in porang

1 containing calcium oxalate and *S. crispus* containing alkaloids, saponins, flavonoids,
 2 potassium, and polyphenols.

3
 4 **Table 3: SGPT blood serum levels of rats in acute toxicity study of porang and *S-crispus* macerated**
 5 **porang flour**

SGPT (U/L)	NPF6 (mean±SD)	SPF6 (mean±SD)	NPF7 (mean±SD)	SPF7 (mean±SD)
24 h				
Pre	18.74 ± 0.26	18.45 ± 0.34	18.45 ± 0.59	18.06 ± 0.63
Post	18.16 ± 0.65	18.64 ± 0.43	24.96 ± 0.55	23.88 ± 0.41
P-value ¹	0.109	0.178	0.000*	0.000*
Δ	-0.58 ± 0.63	0.20 ± 0.27	6.51 ± 0.27	5.83 ± 0.97
P-value ²		0.035*		0.170
72 h				
Pre	18.74 ± 0.26	18.45 ± 0.34	18.45 ± 0.59	18.06 ± 0.63
Post	18.45 ± 0.34	18.35 ± 0.53	23.40 ± 0.40	23.40 ± 0.40
P-value ¹	0.209	0.800	0.000*	0.001*
Δ	-0.29 ± 0.43	-0.10 ± 0.80	4.95 ± 0.80	5.34 ± 0.49
P-value ²		0.643		0.378

6 *Significant (p<0.05) with ¹ paired t-tests to compare pre- and post- result; ² independent t-tests to compare
 7 NPF (natural porang flour) and SPF (*S. crispus* macerated porang flour). NPF6, NPF7 or SPF6, SPF7 were
 8 administered with the dose of 2000 and 5000 mg/kg BW, respectively.

9
 10 **Conclusions**

11 Based on the acute toxicity study, it can be concluded that porang and porang
 12 macerated with *S. crispus* were not toxic until the highest dose of 5000 mg/kg BW. It was
 13 proved by the absence of LD50, no change in behavior, no weight losses, and also the
 14 results of biochemical tests, such as urea protein, SGOT, and SGPT which were still in
 15 the normal range. It is necessary to carry out further toxicity studies, including sub chronic
 16 to determine the safety level of porang and *S. crispus* consumption for long period.

17
 18 **Acknowledgments**

19 The authors would like to thank Alma Ata University for the many facilities for this
 20 study.

21
 22 **References**

- 23 1. Zhang Y, Xie B, Gan X. Advance in the applications of konjac glucomannan and
 24 its derivatives. Carbohydr Polym. 2005;60:27–31.
 25 2. Devaraj RD, Reddy CK, Xu B. Health-promoting effects of konjac glucomannan
 26 and its practical applications: A critical review. Int J Biol Macromol [Internet].
 27 2019;126:273–81. Available from:
 28 <https://doi.org/10.1016/j.ijbiomac.2018.12.203>.
 29 3. Vuksan V, Sievenpiper JL, Owen R, Swilley JA, Spadafora P, Jenkins DJA, et al.
 30 Beneficial effects of viscous dietary fiber from Konjac-Mannan in subjects with
 31 the insulin resistance syndrome: Results of a controlled metabolic trial. Diabetes

- Care. 2000;23(1):9–14.
4. Chen H, Nie Q, Hu J, Huang X, Zhang K, Pan S, et al. Hypoglycemic and Hypolipidemic Effects of Glucomannan Extracted from Konjac on Type 2 Diabetic Rats. *J Agric Food Chem.* 2019;67(18):5278–88.
 5. Zheng J, Li H, Zhang X, Jiang M, Luo C, Lu Z, et al. Prebiotic Mannan-Oligosaccharides Augment the Hypoglycemic Effects of Metformin in Correlation with Modulating Gut Microbiota. *J Agric Food Chem.* 2018;66(23):5821–31.
 6. Ernawati E, Aprilia V, Pangastuti R. The increase of blood creatinine levels and the gastric histopathology of rat after feeding of porang (*Amorphophallus oncophyllus*) flour treated with *Strobilanthes crispus*. *Indones J Nutr Diet.* 2018;6(3):113–21.
 7. Pramathana A. The characteristics of porang flour with the variation of ash and salt soaking in reducing oxalic acid. Universitas Jember; 2013 (In Indonesian).
 8. Mawarni RT, Widjanarko SB. The effect of Ball mill method and chemically purification in reducing calcium oxalate. *J Pangan dan Agroindustri.* 2015;3(2):571–81 (In Indonesian).
 9. Sanjaya MITF, Kunarto B, Wahjuningsih SB. The combination effect of soaking in NaCl and size particle on glucomannan, calcium oxalate, and food fiber content in porang flour (*J Teknol Pangan dan Has Pertan.* 2012;9(2):16–23 (In Indonesian).
 10. Astuti RD, Prastowo A, Aprilia V. Porang flour (*Amorphophallus oncophyllus*) with and without soaking of keji beling extract increases the value of ureum on toxicity test in wistar rat (*Rattus norvegicus*). *Indones J Nutr Diet.* 2017;5(3):93–7.
 11. Noonan SC. Oxalate content of foods and its effect on humans. *Asia Pac J Clin Nutr.* 1999;8(1):64–74.
 12. Faridah A, Widjanarko SB. Optimization of multilevel ethanol leaching process of porang flour (*Amorphophallus muelleri*) using response surface methodology. *Int J Adv Sci Eng Inf Technol.* 2013;3(2):74–80.
 13. Dewi MS. Learning about The Solution Ability of Calcium Oxalate in *Strobilanthes crispus* leaf extract and water fraction. Universitas Andalas; 2009.
 14. BPOM RI. Regulation of The Head of The Food and Drug Supervisory Agency of The Republic of Indonesia No. 7, 2014 concerning Guidelines for In Vivo Non Clinical Toxicity Test. 2014.
 15. Mistry K. Chronic kidney disease. *Clin Pediatr Nephrol Third Ed.* 2016;315(20):601–26.
 16. Krysanti A, Widjanarko SB. Subacute Toxicity Testing of Glucomannan (*A. muelleri* Blume) Toward SGOT and Sodium of Wistar Rats by In Vivo. *J Pangan dan Agroindustri.* 2014;2(1):1–6.
 17. Natalia ED, Widjanarko SB, Ningtyas DW. Acute Toxicity Test Of Glucomannan Flour (*A. muelleri* Blume) Toward Potassium Of Wistar Rats. *J Pangan dan Agroindustri.* 2014;2(1):132–6.

- 1 18. Aprilia V, Nurinda E, Alpina L, Hadi H, Ariftiyana S, Kurniasari Y. Reduction
2 procedure of calcium oxalate in porang flour by maceration of *Strobilanthes crista*
3 [Internet] [Internet]. Indonesia; S00202006668, 2020. Available from:
4 [https://pdki-](https://pdki-indonesia.dgip.go.id/detail/S00202006668?type=patent&keyword=proses+reduksi+kalsium+oksalat)
5 [indonesia.dgip.go.id/detail/S00202006668?type=patent&keyword=proses+reduk](https://pdki-indonesia.dgip.go.id/detail/S00202006668?type=patent&keyword=proses+reduksi+kalsium+oksalat)
6 [si+kalsium+oksalat](https://pdki-indonesia.dgip.go.id/detail/S00202006668?type=patent&keyword=proses+reduksi+kalsium+oksalat).
- 7 19. OECD. OECD Guidelines for Testing og Chemicals. Test No. 420: Acute Oral
8 Toxicity – Fixed Dose Procedure (chptr). 2001;(December):1–14.
- 9 20. Hodge A, Sterner B. Toxicity Classes. In: Canadian Center for Occupational
10 Health and Safety; 2005.
- 11 21. Mundt, L. dan Shanahan K. Graff’s Textbook of Urinalysis and Body Fluids.
12 Kluwer W, editor. Philadhelpia; 2010.
- 13 22. Harris, P., Mann, L., Phillips, B., Webster C. Diabetes management in general
14 practice gideline for type 2 diabetes. Australia: Diabetes Australia; 2011.
- 15 23. Wicaksono MA. The evaluation of renal and hepatic function of female rats
16 (Sprague-Dawley) as the impact of administration of Galohgor jamu. Bogor
17 Agricultural University; 2010. (In Indonesian).
- 18 24. Korth KL, Doege SJ, Park S-H, Goggin FL, Wang Q, Gomez SK, et al. Medicago
19 truncatula mutants demonstrate the role of plant calcium oxalate crystals as an
20 effective defense against chewing insects. *Plant Physiol*. 2006;141(1):188–95.
- 21 25. Keppel, J., Calissi P. Safe Drug Prescribing for Patients with Renal Insufficiency.
22 *Can Med Assoc J*. 2002;166(6):473–7.
- 23 26. Albright Jr RC. Acute Renal Failure: A Practical Update. *Mayo Clin Proc*.
24 2001;76:67–74.
- 25 27. Wilcox CR, Whitehurst LA, Somani BK, Cook P. Kidney stone disease: An update
26 on its management in primary care. *Br J Gen Pract*. 2020;70(693):205–6.
- 27 28. Ratkalkar VN, Kleinman JG. Mechanisms of Stone Formation.
- 28 29. Mitruka BM. Clinical Biochemical and Hematological Reference Values in
29 Normal Experimental Animals and Normal Humans. 2nd ed. Chicago: Masson
30 Publishing; 1981.
- 31 30. Donowarti I, Widjanarko SB, Yunianta Y, Pudjiastuti P. Acute toxicity test of low
32 calcium oxalate porang (*Amorphophallus muelleri* Blume) flour. *Iraqi J Agric Sci*.
33 2021;52(1):218–31.
- 34 31. Loeb, W. F., Quimbly FW. *The Clinical Chemistry of Laboratory Animals*.
35 London: Pergamon Press Inc; 1989.
- 36 32. Shad, J. A., Brann OS. Acute Hepatitis After Ingestion of Herbs. *South Med J*.
37 1999;92(11):1095–7.
- 38 33. Laliberte, L., Villeneuve JP. Hepatitis After The Use of Germander, A Herbal
39 Remedy. *Can Med Assoc J*. 1996;154(11):1689–92.
- 40 34. Currie, B. J., Clough AR. Kava Hepatotoxicity With Western Herbal Products:
41 Does It Occur With Traditional Kava Use? *Med J Aust*. 2003;178:421–2.



verianiaprilia verianiaprilia <verianiaprilia@almaata.ac.id>

[OAMJMS] Editor Decision

1 pesan

Prof. Dr Mirko Spiroski via SFS - Journals (Scientific Foundation SPIROSKI - Journals), Skopje, Republic of Macedonia <noreply@publicknowledgeproject.org> 19 Agustus 2021 pukul 13.12
Balas Ke: "Prof. Dr Mirko Spiroski" <mspiroski@id-press.eu>
Kepada: Rizka Qurrota A'yun <rizka.qurrotaa@gmail.com>, Uswatun Hasanah <uswa0607@gmail.com>, Hamam Hadi <hhadi@almaata.ac.id>, Mustofa <mustofajogja@yahoo.com>, Eva Nurinda <evanurinda@almaata.ac.id>, Yulinda Kurniasari <kurniasari.yulinda@almaata.ac.id>, Veriani Aprilia <verianiaprilia@almaata.ac.id>

Rizka Qurrota A'yun, Uswatun Hasanah, Hamam Hadi, Mustofa, Eva Nurinda, Yulinda Kurniasari, Veriani Aprilia (Author):

We have reached a decision regarding your submission to Open Access Macedonian Journal of Medical Sciences, "An Acute Toxicity Study of Porang (*Amorphophallus oncophyllus*) Flour Macerated with *Strobilanthes crispus* in Wistar Rats", Manuscript ID = OJS6813.

Our decision is: Revise your manuscript until September 15, 2021 and submit on the OAMJMS website.

Sincerely,
Prof. Dr Mirko Spiroski,
Editor-in-Chief, OAMJMS

Reviewer B:
Recommendation: Accept Submission

Reviewer C:
Recommendation: Decline Submission

Reviewer D:
Recommendation: Revisions Required

Reviewer E:

The manuscript is well written and presented. Having read the manuscript, I have the following comments:

1. For the main study of NPF6, NPF7, SPF6, and SPF7 please provide the additional study results of body weight. Does it affect the body weight of the animals with those high doses?

2. On page 6 paragraph 1, the authors declared to exclude the congestion and hemorrhage, but in figure 2, authors include these parameters. Authors should be consistent in making a statement that represents the results.
3. Please add the scale bar in Figure 2.
4. If possible, please provide a picture/arrow of calcium oxalate formation in the kidney. It is very possible that the calcium oxalate will be accumulated due to a significantly increased level of calcium oxalate in the body.

Recommendation: Revisions Required



D-veriani-aprilia-manuscript-main-text-macedonian-journal-of-medical-science.docx
319K



verianiaprilia verianiaprilia <verianiaprilia@almaata.ac.id>

[OAMJMS] Editor Decision

3 pesan

Slavica Hristomanova-Mitkovska, MD, MSc via SFS - Journals (Scientific Foundation SPIROSKI - Journals), Skopje, Republic of Macedonia <noreply@publicknowledgeproject.org> 15 September 2021 pukul 15.55

Balas Ke: "Slavica Hristomanova-Mitkovska, MD, MSc" <cacka_h@yahoo.com>

Kepada: Rizka Qurrota A'yun <rizka.qurrotaa@gmail.com>, Uswatun Hasanah <uswa0607@gmail.com>, Hamam Hadi <hhadi@almaata.ac.id>, Mustofa <mustofajogja@yahoo.com>, Eva Nurinda <evanurinda@almaata.ac.id>, Yulinda Kurniasari <kurniasari.yulinda@almaata.ac.id>, Veriani Aprilia <verianiaprilia@almaata.ac.id>

Rizka Qurrota A'yun, Uswatun Hasanah, Hamam Hadi, Mustofa, Eva Nurinda, Yulinda Kurniasari, Veriani Aprilia (Author):

We have reached a decision regarding your submission to Open Access Macedonian Journal of Medical Sciences, "An Acute Toxicity Study of Porang (*Amorphophallus oncophyllus*) Flour Macerated with *Strobilanthes crispus* in Wistar Rats", Manuscript ID = OJS6813, submitted {\$submission}

Our decision is to: accept the revised Manuscript for publishing.

SciRev (<https://scirev.org/>) offers you the possibility to share your experience with the scientific review process with your colleagues (left search engine) and to select an efficient journal for submitting your manuscripts (right search engine). Because we would like to increase the quality of the review process, please register and submit your experience with the review process of your article published in Open Access Macedonian Journal of Medical Sciences in the SciRev (<https://scirev.org/questionnaire/macedonian-journal-of-medical-sciences/>).

**G-revisi 1_veriani-aprilia-manuscript-main-text-macedonian-journal-of-medical-science.docx**
322K

verianiaprilia verianiaprilia <verianiaprilia@almaata.ac.id>
Kepada: "Slavica Hristomanova-Mitkovska, MD, MSc" <cacka_h@yahoo.com>

18 September 2021 pukul 01.57

Dear Mitkovska

We are very happy to hear from you that our paper has been accepted.
Please inform us of the next steps to continue the publication process.

Regards
Veriani Aprilia

[Kutipan teks disembunyikan]

Slavica Hristomanova <cacka_h@yahoo.com>
Kepada: verianiaprilia verianiaprilia <verianiaprilia@almaata.ac.id>

20 September 2021 pukul 00.35

Dear Verani Aprilia,

Congratulations on your paper. In the next few days you will receive an Email with further instructions about the fee, copy editing and publication steps and processes.

Best regards,
Slavica Hristomanova Mitkovska

7/20/23, 1:22 AM

Email Universitas Alma Ata - [OAMJMS] Editor Decision

[Kutipan teks disembunyikan]



verianiaprilia verianiaprilia <verianiaprilia@almaata.ac.id>

[OAMJMS] Regular Publication Fee

2 pesan

Prof. Dr Mirko Spiroski via SFS - Journals (Scientific Foundation SPIROSKI - Journals), Skopje, Republic of Macedonia <noreply@publicknowledgeproject.org>
Balas Ke: "Prof. Dr Mirko Spiroski" <mspiroski@id-press.eu>
Kepada: Veriani Aprilia <verianiaprilia@almaata.ac.id>

10 Oktober 2021
pukul 15.03

Dear Veriani Aprilia,

Please find details for your Regular Publication Fee of 400 € (EUR) for the manuscript "An Acute Toxicity Study of Porang (Amorphophallus oncophyllus) Flour Macerated with Strobilanthes crispus in Wistar Rats " [oamjms.2021.6813], which should be prepared for publication in Open Access Maced J Med Sci (OAMJMS) and should be transferred in the next seven days.

If you intend to cancel your publication, please, send me information.

You can transfer Regular Publication Fee:

- online with the Visa credit card by the following link: <https://oamjms.eu/index.php/mjms/pubfees>
- or transfer Regular Publication Fee by the bank account:

Beneficiary: Scientific Foundation SPIROSKI, [Rajko Zhinzifov No 48, Skopje, Republic of Macedonia](#). IBAN CODE: MK07210722000034890, VAT Number: 4030004519877
Beneficiary's Bank: NLB BANKA AD SKOPJE, SWIFT code = TUTNMK22, Address = Mother Teresa 1, Country = Macedonia
Details: DOI = OAMJMS.2021.6813

Please, note that enclosed invoice and online transfer are different accounts, but both are legitimate!
Please, include your document of the transfer on the website.

Cordially,
Prof. Dr Mirko Spiroski

verianiaprilia verianiaprilia <verianiaprilia@almaata.ac.id>
Kepada: "Prof. Dr Mirko Spiroski" <mspiroski@id-press.eu>

11 Oktober 2021 pukul 13.02

Dear Prof Spiroski,

Thank you for your information?
Could I get the file of invoice?
I did not find it in my account.
Thank you

Regards,
Veriani Aprilia
[Kutipan teks disembunyikan]



verianiaprilia verianiaprilia <verianiaprilia@almaata.ac.id>

payment of publication fee

1 pesan

verianiaprilia verianiaprilia <verianiaprilia@almaata.ac.id>

21 Oktober 2021 pukul 09.38

Kepada: "Prof. Dr Mirko Spiroski <mspiroski@id-press.eu>,, Prof. Dr Mirko Spiroski" <mspiroski@yahoo.com>

Dear Prof. Dr. Mirko Spiroski


We have transferred a publication fee "An Acute Toxicity Study of Porang (*Amorphophallus oncophyllus*) Flour Macerated with *Strobilanthes crispus* in Wistar Rats ", Manuscript ID = OJS6813 via bank account.

Please find the receipt in the attachment. I also attached it to my OAMJMS account.

Hope the publication processing will be done soon.

Thank you very much

Regards,
Veriani Aprilia

 **article fee receipt.pdf**
1052K



verianiaprilia verianiaprilia <verianiaprilia@almaata.ac.id>

[OAMJMS] New notification from Open Access Macedonian Journal of Medical Sciences

1 pesan

**Prof. Dr. Mirko Zhivko Spiroski via SFS - Journals (Scientific Foundation SPIROSKI - Journals),
Skopje, Republic of Macedonia** <noreply@publicknowledgeproject.org>
Balas Ke: "Prof. Dr Mirko Spiroski" <mspiroski@yahoo.com>
Kepada: Veriani Aprilia <verianiaprilia@almaata.ac.id>

31 Oktober 2021
pukul 19.22

You have a new notification from Open Access Macedonian Journal of Medical Sciences:

An issue has been published.

Link: <https://oamjms.eu/index.php/mjms/issue/current>

Prof. Dr Mirko Spiroski



verianiaprilia verianiaprilia <verianiaprilia@almaata.ac.id>

[OAMJMS] Editor Decision

1 pesan

Teodora Fildishevskia via SFS - Journals (Scientific Foundation SPIROSKI - Journals), Skopje, Republic of Macedonia <noreply@publicknowledgeproject.org> 2 November 2021
pukul 18.56
Balas Ke: Teodora Fildishevskia <tfildishevskia@id-press.eu>
Kepada: Rizka Qurrota A'yun <rizka.qurrotaa@gmail.com>, Uswatun Hasanah <uswa0607@gmail.com>, Hamam Hadi <hhadi@almaata.ac.id>, Mustofa <mustofajogja@yahoo.com>, Eva Nurinda <evanurinda@almaata.ac.id>, Yulinda Kurniasari <kurniasari.yulinda@almaata.ac.id>, Veriani Aprilia <verianiaprilia@almaata.ac.id>

Rizka Qurrota A'yun, Uswatun Hasanah, Hamam Hadi, Mustofa, Eva Nurinda, Yulinda Kurniasari, Veriani Aprilia (Author):

The editing of your submission, "An Acute Toxicity Study of Porang (*Amorphophallus oncophyllus*) Flour Macerated with *Strobilanthes crispus* in Wistar Rats ," Manuscript ID = OJS6813 is complete. We are now sending it to production.

Submission URL: <https://oamjms.eu/index.php/mjms/authorDashboard/submission/6813>

Copyright Form

Manuscript Number: OJS6813

This Agreement is made with *Open Access Macedonian Journal of Medical Sciences (OAMJMS)*. The Agreement is for the Article submitted by you ("Author") for publication *Open Access Macedonian Journal of Medical Sciences (OAMJMS)*. To enable publishing the Article in *Open Access Macedonian Journal of Medical Sciences (OAMJMS)* ("the Journal"), the ownership of copyright must be established. Please read and complete the form below (Section A plus Section B) and return one copy to the address given below. There are explanatory notes to this Agreement, which also form part of the Agreement.

The Article cannot be published until this signed Agreement is received by OAMJMS.

SECTION A: Author's Warranty (Please print your details)

Name: Veriani Aprilia

Address: Department of Nutrition, Faculty of Health Sciences, Universitas Alma Ata, Jl. Brawijaya No. 99, Tamantirto, Kasihan, Bantul, Yogyakarta 55183, Indonesia

Article title: Acute Toxicity Study of Porang (*Amorphophallus oncophyllus*) Flour Macerated with *Strobilanthes crispus* in Wistar Rats

Names of all authors in the order in which they appear in the Article:

Rizka Qurrota A'yun
Uswatun Hasanah
Hamam Hadi
Mustofa
Eva Nurinda
Yulinda Kurniasari
Veriani Aprilia

In consideration of the publication of the Article in the above Journal, I hereby warrant and undertake:

- that this Article is an original work, has not been published before and is not being considered for publication elsewhere in its final form either in printed or electronic form.
- that I have obtained permission from the copyright holder to reproduce in the Article (in all media including print and electronic form) material not owned by me, and that I have acknowledged the source;
- that this Article contains no violation of any existing copyright or other third party right or any material of an obscene, indecent or otherwise unlawful nature and that to the best of my knowledge this Article does not infringe the rights of others;
- that I will indemnify and keep indemnified the Editors, Open Access Macedonian Journal of Medical Sciences against all claims and expenses (including legal costs and expenses) arising from any breach of this warranty and the other warranties on my behalf in this Agreement;
- that in the case of a multi-authored Article I have obtained copyright assignment from all co-authors, in writing, and authorization to enter into this Agreement on their behalf and that all co-authors have read and agreed the above warranties;



Author: Signed: . Veriani Aprilia Date: November 12, 2021.

SECTION B: Copyright Assignment

This is an open-access article distributed under the terms of the Creative Commons Attribution License, which permits unrestricted use, distribution, and reproduction in any medium, provided the original author and source are credited. Notwithstanding the above, I retain all proprietary rights other than copyright, such as patent and trade mark rights and rights to any process or procedure described in the Article.



Author: Signed: . Veriani Aprilia Date: November 12, 2021.

In signing this form, the signee asserts that any authors not signing have authorised the signee to do so on their behalf, and that the manuscript submitted has been approved by these authors in the form in which it has been submitted, and that the warranties given above have been read and agreed by all authors.



Acute Toxicity Study of Porang (*Amorphophallus oncophyllus*) Flour Macerated with *Strobilanthes crispus* in Wistar Rats

Rizka Qurrota A'yun¹, Uswatun Hasanah¹, Hamam Hadi², Mustofa³, Eva Nurinda⁴, Yulinda Kurniasari¹, Veriani Aprilia^{1*}

¹Department of Nutrition, Faculty of Health Sciences, Universitas Alma Ata, Kasihan, Yogyakarta, Indonesia; ²Department of ???, Graduate School of Public Health, Universitas Alma Ata, Kasihan, Yogyakarta, Indonesia; ³Department of Pharmacology and Therapy, Faculty of Medicine, Public Health, and Nursing, Universitas Gadjah Mada, Jalan Farmako, Yogyakarta, Indonesia; ⁴Department of Pharmacy, Faculty of Health Sciences, Universitas Alma Ata, Kasihan, Yogyakarta, Indonesia

Abstract

Edited by: <https://publons.com/researcher/391987/mirko-spiroski>

Citation: A'yun RQ, Hasanah U, Hadi H, Mustofa, Nurinda E, Kurniasari Y, Aprilia V. Acute Toxicity Study of Porang (*Amorphophallus oncophyllus*) Flour Macerated with *Strobilanthes crispus* in Wistar Rats. Open Access Maced J Med Sci. 2021 Feb 05; 9(A):1-6. <https://doi.org/10.3889/oamjms.2021.6813>

Keywords: *Amorphophallus oncophyllus*; *Strobilanthes crispus*; LD50; Urinary protein; Serum glutamic oxaloacetic transaminase; Serum glutamic pyruvic transaminase

*Correspondence: Veriani Aprilia, Department of Nutrition, Faculty of Health Sciences, Universitas Alma Ata, Kasihan, Yogyakarta, Indonesia. E-mail: verianiaprilia@almaata.ac.id

Received: ???

Revised: ???

Accepted: ???

Copyright: © 2021 Rizka Qurrota A'yun,

Uswatun Hasanah, Hamam Hadi, Mustofa, Eva Nurinda, Yulinda Kurniasari, Veriani Aprilia

Funding: This research did not receive any financial support

Competing Interests: The authors have declared that no competing interests exist

Open Access: This is an open-access article distributed under the terms of the Creative Commons Attribution-NonCommercial 4.0 International License (CC BY-NC 4.0)

BACKGROUND: Porang (*Amorphophallus oncophyllus*) is a local tuber food that high in bioactive compound glucomannan. It uses are limited due to oxalate acid content which poses health risks. *Strobilanthes crispus* leaves could reduce the level of calcium oxalate in porang. However, there is still no study to prove its safety.

AIMS: This study aimed to investigate the acute oral toxicity study of porang (*A. oncophyllus*) macerated with *S. crispus* based on observation of mortality rate (LD50), the changes in behavior during 72 h, renal and hepatic function such as urinary protein, serum glutamic oxaloacetic transaminase (SGOT), and serum glutamic pyruvic transaminase (SGPT) levels of Wistar rat (*Rattus norvegicus*)

METHODS: An acute toxicity test was conducted based on the Organization of Economic Co-Operation and Development 420 Fixed-Dose Procedure Guideline that consists of preliminary and main studies. For the preliminary study, rats were divided into control and five treatment groups with the dosage of 50, 300, 2000, and 5000 mg/kg body weight (BW) for each natural porang flour (NPF) and *S. crispus*-macerated porang flour (SPF). For the main study, rats were divided into four groups, those were NPF and SPF with the dosage of 2000 and 5000 mg/kg BW. Levels of urinary protein and blood serum SGOT and SGPT levels were measured at 0, 24, and 72 after treatment.

RESULTS: The acute toxicity study showed that porang and porang macerated with *S. crispus* were not toxic until the highest dose of 5000 mg/kg BW. It was proved by the absence of LD50, no change in behavior, no weight losses, and also the results of biochemical tests, such as urinary protein, SGOT, and SGPT which were still in the normal range.

CONCLUSIONS: Porang flour and SPF were concluded as non-toxic food based on acute toxicity study.

Introduction

Porang or iles-iles is included in the genus of *Amorphophallus*. These plants wildly grow in the jungle, under the bamboo tree, along the riverside, and mountain slope [1]. Porang tuber (*Amorphophallus oncophyllus*) contains glucomannan or known as mannan. Glucomannan is a water-dissolved food fiber that is low in calories and has a special function for diet, so that it has been widely used for food products [2]. The food containing glucomannan reduced cholesterol level, blood sugar, and hypertension [3]. Its relatively low glycemic index could decrease blood sugar level and made this tuber was good to be consumed by diabetic patients. It proved to boost the therapy of diabetes type 2 through lipid metabolism improvement [4], while other study reported that glucomannan worked in synergy with metformin to increase its hypoglycemia effect [5].

Even though it had been proven that there were many benefits of glucomannan, the utilization of porang tuber as the source of glucomannan is

still low. This is caused by the homemade product of porang still has the weakness, that is itchy when consumed. This itchiness is caused by the content of oxalate [6], [7], [8], [9]. Oxalate acid consumption in a high number increased blood creatinine and urea levels [6], [10]. It also decreased the bioavailability of calcium inside the body, formed kidney stones, can cause corrosion of the mouth and gastrointestinal tract, kidney failure, and hematuria [11].

Various efforts had been carried out to reduce the level of calcium oxalate level in porang tuber, both mechanically using stamp mill and blower, ball mill, also chemically using NaCl [8], [9], [12]. The research using natural or herbal ingredients in reducing oxalate calcium content is still limited. In a previous study, the ethanol extract of *Strobilanthes crispus* leaves reduced the level of calcium oxalate in porang flour [13], but it still needs to be proved before consumption for its safety. Therefore, *in vivo* toxicity test is needed to be carried out.

A toxicity test is a set of analyses to detect the toxic effect of a substance on the biological system

and to obtain typical dose-response data from the test preparation [14]. In addition, a toxicity test can be carried out to determine the toxic effects on the vital organs of the animal, such as the kidneys and liver. One of the kidney functions is to excrete foreign compounds such as drugs, food, pesticides, and other non-nutritional exogenous materials that enter the body [15]. The study of the level of porang toxicity was reported on porang tubers [16], [17], but its combination with *S. crispus* needs to be studied further.

In this study, an acute toxicity test was conducted by observing the mortality rate (LD50) and the changes in behavior during 72 h. To confirm the kidney and liver function, the urea protein tests, kidney histopathology, and biochemical tests of aminotransferase enzyme activity (serum glutamic oxaloacetic transaminase [SGOT] and serum glutamic pyruvic transaminase [SGPT]) were also done.

Materials and Methods

Plant materials and sample preparation

Porang was purchased from the farmer in Madiun, East Java. It was directly processed into flour at the laboratory. Porang flour macerated with *S. crispus* was then produced based on the Patent Application No. S00202006668 [18].

Experimental animals

Non-pregnant female Wistar (*Rattus norvegicus*) rats weighing 110–180 g with the age of 8–12 weeks were used in this acute study. Female rats were used because they were more sensitive than male rats [14]. For the preliminary study, 11 rats were used. Each of them was represented as a treatment group based on the dose of oral feeding, that is, control (distilled water treatment), natural porang flour (NPF1), NPF2, NPF3, NPF4, NPF5, and (*S. crispus*-macerated porang flour [SPF1], SPF2, SPF3, SPF4, and SPF5 for) for the dose of 50, 300, 2000, and 5000 mg/kg of bodyweight (BW), respectively. For the main study, twenty rats were divided into four groups, that is, NPF6 (dose of 2000 mg/kg BW), NPF7, SPF6, and SPF7.

An acute toxicity study was conducted based on the Organization of Economic Co-Operation and Development Guideline 420 for testing chemicals. The procedures consisted of two steps; those were preliminary and main analysis. For preliminary analysis, the rats were orally administered with porang flour or SPF with doses of 5, 50, and 300 mg/kg BW. If there was no mortality, the dose was increased up to

2000 mg/kg BW. For the main analysis, the doses used were 2000 mg/kg BW and 5000 mg/kg BW [19].

The acclimatization of animals was 5 days and fed with free access to standard laboratory diet and *ad libitum* water. They were then fasted for 18 h before administered with the flours. The mortality, any injury, or illness, physical appearance, behavior changes (step backward, walk with the stomach, and sleepy), diarrhea were observed visually after the first 30 min and every 1 h for 24 h. If there was no sign of toxicity, the test was completed until 72 h. The BW of rats was monitored at the beginning and the end of the analysis. The urine and blood samples were collected before treatment, 24 h and 72 h after treatment for determining the urinary protein levels, SGOT, and SGPT levels, respectively. At the end of the study, rats were euthanized by decapitation, the kidney organs were excised carefully, then preserved in 10% buffered formalin before the histopathological study.

Urinary protein levels were analyzed by the pyrogallol red-molybdate method. SGOT and SGPT were analyzed by Optimized UV-test according to International Federation of Clinical Chemistry and Laboratory Medicine [14].

Statistical analysis

Data were performed by mean values, followed by statistical analysis used SPSS ver. 16. The differences between samples were tested by analysis of variance with Duncan's multiple range test. Differences were significant when $p < 0.05$.

Results and Discussion

Acute oral toxicity study

The first acute oral toxicity study was preliminary. This study was important to find the starting dose that must be done in the main study because there was still no study about the toxicity of porang with the combination of *S. crispus*. The study showed that there was no mortality (LD50), injury, physical appearance, or behavior changes from the first 30 min until 72 h observations, for both NPF and SPF groups. The data were used as the reason to conduct the main study with the dose of 2000 mg/kg BW and 5000 mg/kg BW.

The main study was also showed no toxicity sign and mortality in all groups. Because the maximum dose did not cause mortality, LD50 was stated as apparent LD50. Based on The Hodge and Sterner Toxicity Scale, porang both natural and macerated with *S. crispus* were categorized as practically non-toxic

due to no mortality (LD50) at the administration dose of 5000–15000 mg/kg BW [20].

BW of rats

Figure 1a showed the BW of rats during 72 h of preliminary study. The BW of rats in this preliminary test did not show the weight loss that was in line with the results of the main study [10]. For this acute oral toxicity study, the administration of porang flour was once in the beginning of study and the BW was measured at the beginning and the end of study. The additional study with the administration of high doses porang (NPF6, NPF7, SPF6, and SPF7) and control with the frequency of once/day during 3 days was also conducted (Figure 1b). It was done to strengthen the answer whether there was the effect of porang administration on BW of rats. The data showed that there was the increase of BW in all treatments with the similar rates; those were about 5–6 g.

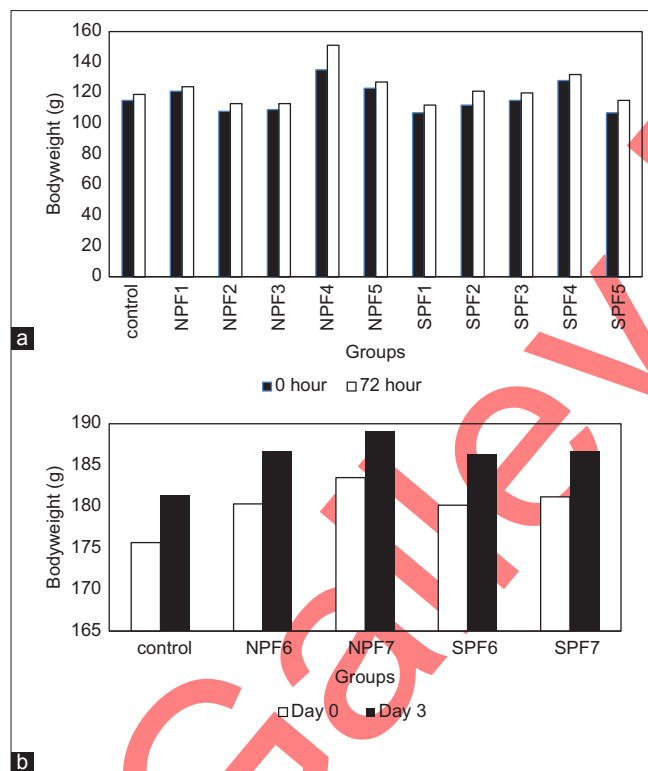


Figure 1: Bodyweight of rats in acute toxicity study of natural porang and *S. crispus*-macerated porang flour (a) with the administration only at the beginning of preliminary study (control: Distilled water treatment, NPF: Natural porang flour, SPF: *S. crispus*-macerated porang flour. NPF1, NPF2, NPF3, NPF4, NPF5 and SPF1, SPF2, SPF3, SPF4, SPF5, for the dose of 50, 300, 2000, and 5000 mg/kg body weight [BW], respectively); (b) with the administration of once/day during 3 days of study (control: Distilled water treatment, NPF6, NPF7, and SPF6, SPF7 for the dose of 2000 and 5000 mg/kg BW, respectively)

This data showed that there was no absence of weight loss during administration of porang. It indicated that their growth was normal or there was no indication of impaired absorption of nutrients due to the oral administration of porang flour both natural and macerated with *S. crispus*.

Urinary protein levels and histopathological examination of kidney organ

The effect of the administration of porang flour on urinary protein levels was shown in Table 1. All groups showed urinary levels under 200 mg/L that categorized as normal levels [21]. However, there was an increase observed in NPF7 and SPF7 both in 24 h and 72 h of administration and NPF6 after 72 h of administration ($p < 0.05$). It indicated that the elevation of protein levels may be seen at a shorter time when a higher dose was applied.

The increase of protein levels in the urine indicated a progression to a reduction in renal performance [22]. This study was relevant to the previous publication of the same study which showed an increase in urea and creatinine levels which can be used as an indicator of kidney function/performance [6], [10]. In another study, the administration of the herbal medicine of galohgor also showed an increase in urea level, creatinine, and urinary protein [23]. In this study, the decrease was still within the normal range, therefore it is necessary to confirm with further toxicity tests of sub chronic and others to find out whether in a longer period of studies there will be a gradual reduction in kidney performance.

In this study, there was no difference in urea protein levels between the NPF and SPF groups, which indicated that immersion in *S. crispus*, which is one of the herbal medicines, did not affect increasing urea protein levels. However, porang flour contains components that can cause the risk of damage to the kidneys, namely, calcium oxalate. Calcium oxalate had an impact on mechanical abrasion of the gastrointestinal tract and renal smooth tubules [24]. In another study, the administration of herbal medicine caused acute tubular necrosis or fibrotic interstitial nephritis that occurred rapidly and progressively. This syndrome was characterized by progressive renal failure, the discovery of a lot of urine sediment, shrinkage of kidney size with mild proteinuria, and was associated with the incidence of urothelial cancer [25], [26]. Calcium oxalate may also form the kidney stone that the incidence is rising recently with the lifetime risk of 10–15% [27]. This clinical stone formation begins from the nucleation of crystal either in supersaturated renal tubular fluid or in the renal interstitial fluid. This may be influenced by the rising of stone component molecules, the lowering of urine volume, the changing of pH, or the combining of these factors. The crystal may growth in size that may combine with some intrarenal structure and further nucleation to generate the stone [28].

As a confirmation test for the effect of oral administration of porang flour, this study also conducted a kidney histopathology test (Figure 2). Histopathology of the kidney showed that all renal organs changed in terms of anatomical pathology in the form of congestion, except for the NPF7 group which was in the form of hemorrhage. Mild congestion was found in the control, NPF6, and SPF6 groups, while the most severe congestion was seen in SPF7. Congestion and

Table 1: Urinary protein levels of rats in acute toxicity study of porang and SPF

Urinary Protein (mg/L)	NPF6 (mean ± SD)	SPF6 (mean ± SD)	NPF7 (mean ± SD)	SPF7 (mean ± SD)
24 h				
Pre	62.32 ± 7.23	59.45 ± 4.78	60.33 ± 6.03	60.33 ± 2.29
Post	62.74 ± 6.83	59.29 ± 3.90	77.77 ± 2.11	74.92 ± 4.73
p-value ¹	0.235	0.783	0.004*	0.005*
Δ	0.42 ± 0.68	-0.16 ± 1.18	17.43 ± 6.68	14.59 ± 5.68
p-value ²	0.370		0.489	
72 h				
Pre	62.32 ± 7.23	59.45 ± 4.78	60.33 ± 6.03	60.33 ± 0.29
Post	65.91 ± 5.60	60.13 ± 4.21	80.50 ± 1.99	76.48 ± 5.21
p-value ¹	0.009*	0.217	0.002*	0.005*
Δ	3.59 ± 1.68	0.68 ± 1.04	20.17 ± 6.41	16.15 ± 6.30
p-value ²	0.011*		0.346	

*Significant ($p < 0.05$) with ¹paired t-tests to compare pre- and post- result; ²independent t-tests to compare NPF and SPF. NPF6, NPF7 or SPF6, SPF7 were administered with the dose of 2000 and 5000 mg/kg BW, respectively. NPF: natural porang flour, SPF: *S. crispus* macerated porang flour.

hemorrhage were a natural process that usually occurs after decapitation. Decapitation leads to tissue injury which causes an increase in blood flow to organs, one of which is the kidneys. In kidney congestion, there is an increase in venous blood pooling in the renal vascular that may be due to physiological conditions, passive blood pressure, and secondary effects to hypovolemic shock, insufficiency, and hypostatic cardiac. In this condition, capillary dilation occurs due to vasodilator stimulation so that the vascularization at the site of the injury widens and contains stagnant blood. Meanwhile, hemorrhage can occur due to the breakdown of blood vessels after congestion or intolerable congestion.

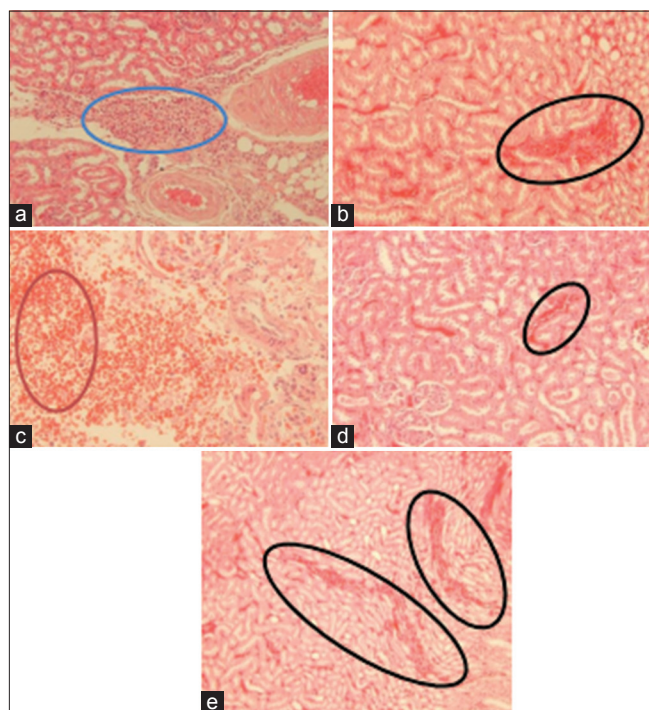


Figure 2: Histopathological examination of kidney organ of the rat in acute oral toxicity study of porang and *S. crispus* macerated porang flour (SPF) (magnification 400 \times): (a) control group, (b) natural porang flour (NPF)6, (c) NPF7, (d) SPF6, (e) SPF7. Blue, red, and black circles describe inflammation, hemorrhage, and congestion, respectively.

SGOT levels of blood serum

SGOT blood serum levels increased significantly in NPF7 and SPF7 groups, both in the observation of 24 h

and 72 h after oral administration ($p < 0.05$) (Table 2). It meant that the high dose of porang and SPF had an impact on SGOT levels. However, the increase was still in the normal range between 36.99 and 42.62 U/L [29]. This study was in line with other subacute toxicity studies that used glucomannan flour with the dose of 4000 mg/kg BW and porang flour in acute toxicity study at a dose of 5000 mg/kg BW [21], [17].

Table 2 also showed that there were no differences between NPF and SPF groups in the dose of 2000 and 5000 mg/kg BW. It indicated that *S. crispus* maceration did not affect the SGOT levels. The increase in SGOT levels affected by the calcium oxalate content which has the risk of damaging the liver cell membrane so that its permeability was impaired, resulting in the SGOT enzyme leaving cells freely, entered the extracellular space and blood vessels beyond normal conditions [17].

In addition, psychological factors occurred due to repeat blood sampling in a relatively short time, leading to stress which also triggered the release of the SGOT enzyme in the blood and increased SGOT levels. Several studies proved that the increase of SGOT enzyme levels did not specifically indicate liver dysfunction, because the enzyme was also found in the skeletal muscles, pancreas, heart, blood vessels of the brain, lungs, and testes [31]. Thus, the increase in SGOT levels was not only caused by damage to the liver cells but also other organs.

SGPT levels of blood serum

SGPT levels of blood serum had a similar result to SGPT, which increased significantly after oral administration of porang in NPF7 and SPF7 groups ($p < 0.05$). However, there was no significant difference between NPF6 and SPF6 groups ($p > 0.05$). These results explain that at higher doses (up to 5000 mg/kg BW), porang both with or without maceration affected the increase of SGPT.

SGPT levels in this study were classified as normal (18.16–24.96 U/L) [29]. However, an increase in SGPT needs attention, because it is an indicator of active hepatocellular damage. Several studies conducted in France, North America, and the Pacific Islands had proven the occurrence of hepatitis in

Table 2: SGOT blood serum levels of rats in acute toxicity study of porang and SPF

SGOT (U/L)	NPF6 (mean ± SD)	SPF6 (mean ± SD)	NPF7 (mean ± SD)	SPF7 (mean ± SD)
24 h				
Pre	37.38 ± 0.77	37.67 ± 0.55	37.38 ± 0.34	36.61 ± 1.22
Post	37.58 ± 0.55	39.03 ± 0.74	45.54 ± 0.93	43.50 ± 0.55
p-value ¹	0.704	0.009*	0.000*	0.000*
Δ	0.19 ± 1.06	1.36 ± 0.63	8.16 ± 1.16	5.83 ± 0.97
p-value ²	0.068		0.158	
72 h				
Pre	37.38 ± 0.77	37.67 ± 0.55	37.38 ± 0.34	36.61 ± 1.22
Post	37.67 ± 0.77	36.99 ± 1.34	42.14 ± 0.41	42.62 ± 0.63
p-value ¹	0.552	0.245	0.000*	0.001*
Δ	0.29 ± 1.01	-0.68 ± 1.12	4.76 ± 0.53	6.02 ± 1.63
p-value ²	0.189		0.138	

*Significant ($p < 0.05$) with ¹paired t-tests to compare pre- and post- result; ²independent t-tests to compare NPF and SPF. NPF6, NPF7 or SPF6, SPF7 were administered with the dose of 2000 and 5000 mg/kg BW, respectively. NPF: natural porang flour, SPF: *S. crispus* macerated porang flour.

Table 3: SGPT blood serum levels of rats in acute toxicity study of porang and SPF

SGPT (U/L)	NPF6 (mean ± SD)	SPF6 (mean ± SD)	NPF7 (mean ± SD)	SPF7 (mean ± SD)
24 h				
Pre	18.74 ± 0.26	18.45 ± 0.34	18.45 ± 0.59	18.06 ± 0.63
Post	18.16 ± 0.65	18.64 ± 0.43	24.96 ± 0.55	23.88 ± 0.41
p-value ¹	0.109	0.178	0.000*	0.000*
Δ	-0.58 ± 0.63	0.20 ± 0.27	6.51 ± 0.27	5.83 ± 0.97
p-value ²	0.035*		0.170	
72 h				
Pre	18.74 ± 0.26	18.45 ± 0.34	18.45 ± 0.59	18.06 ± 0.63
Post	18.45 ± 0.34	18.35 ± 0.53	23.40 ± 0.40	23.40 ± 0.40
p-value ¹	0.209	0.800	0.000*	0.001*
Δ	-0.29 ± 0.43	-0.10 ± 0.80	4.95 ± 0.80	5.34 ± 0.49
p-value ²	0.643		0.378	

*Significant ($p < 0.05$) with ¹paired t-tests to compare pre- and post- result; ²independent t-tests to compare NPF and SPF. NPF6, NPF7 or SPF6, SPF7 were administered with the dose of 2000 and 5000 mg/kg BW, respectively. NPF: natural porang flour, SPF: *S. crispus* macerated porang flour.

patients who consumed herbal ingredients in high doses for long period [32], [33], [34]. Therefore, it needs further studies to know the effects of consuming porang for a longer period on the liver. The tendency of SGPT to increase in this study could be caused by the content of needle-shaped calcium oxalate crystals that may dissolve in the blood and scratch or damage the liver cells. In addition, toxicity may be occurred as the interaction between components in porang containing calcium oxalate and *S. crispus* containing alkaloids, saponins, flavonoids, potassium, and polyphenols.

Conclusions

Based on the acute toxicity study, it can be concluded that porang and porang macerated with *S. crispus* were not toxic until the highest dose of 5000 mg/kg BW. It was proved by the absence of LD50, no change in behavior, no weight losses, and also the results of biochemical tests, such as urea protein, SGOT, and SGPT which were still in the normal range. It is necessary to carry out further toxicity studies, including sub chronic to determine the safety level of porang and *S. crispus* consumption for long period.

Acknowledgments

The authors would like to thank Alma Ata University for the many facilities for this study.

References

- Zhang Y, Xie B, Gan X. Advance in the applications of konjac glucomannan and its derivatives. *Carbohydr Polym.* 2005;60(1):27-31. <http://doi.org/10.1016/j.carbpol.2004.11.003>
- Devaraj RD, Reddy CK, Xu B. Health-promoting effects of konjac glucomannan and its practical applications: A critical review. *Int J Biol Macromol.* 2019;126:273-81. <https://doi.org/10.1016/j.ijbiomac.2018.12.203>
PMid:30586587
- Vuksan V, Sievenpiper JL, Owen R, Swilley JA, Spadafora P, Jenkins DJ, et al. Beneficial effects of viscous dietary fiber from Konjac-Mannan in subjects with the insulin resistance syndrome: Results of a controlled metabolic trial. *Diabetes Care.* 2000;23(1):9-14. <http://doi.org/10.2337/diacare.23.1.9>
PMid:10857960
- Chen H, Nie Q, Hu J, Huang X, Zhang K, Pan S, et al. Hypoglycemic and hypolipidemic effects of glucomannan extracted from konjac on Type 2 diabetic rats. *J Agric Food Chem.* 2019;67(18):5278-88. <http://doi.org/10.1021/acs.jafc.9b01192>
PMid:30964673
- Zheng J, Li H, Zhang X, Jiang M, Luo C, Lu Z, et al. Prebiotic mannan-oligosaccharides augment the hypoglycemic effects of metformin in correlation with modulating gut microbiota. *J Agric Food Chem.* 2018;66(23):5821-31. <http://doi.org/10.1021/acs.jafc.8b00829>
PMid:29701959
- Ernawati E, Aprilia V, Pangastuti R. The increase of blood creatinine levels and the gastric histopathology of rat after feeding of porang (*Amorphophallus oncophyllus*) flour treated with *Strobilanthes crispus*. *Indones J Nutr Diet.* 2018;6(3):113-21.
- Pramathana A. The Characteristics of Porang Flour with the Variation of Ash and Salt Soaking in Reducing Oxalic Acid. Universitas Jember; 2013 (In Indonesian).
- Mawarni RT, Widjanarko SB. He effect of ball mill method and chemically purification in reducing calcium oxalate. *J Pangan Agroind.* 2015;3(2):571-81. (In Indonesian).

9. Sanjaya MI, Kunarto B, Wahjuningsih SB. The combination effect of soaking in NaCl and size particle on glucomanan, calcium oxalate, and food fiber content in porang flour. *J Teknol Pangan Has Pertan.* 2012;9(2):16-23. (In Indonesian).
10. Astuti RD, Prastowo A, Aprilia V. Porang flour (*Amorphophallus oncophyllus*) with and without soaking of keji beling extract increases the value of ureum on toxicity test in wistar rat (*Rattus norvegicus*). *Indones J Nutr Diet.* 2017;5(3):93-7. [http://doi.org/10.21927/ijnd.2017.5\(3\).93-97](http://doi.org/10.21927/ijnd.2017.5(3).93-97)
11. Noonan SC. Oxalate content of foods and its effect on humans. *Asia Pac J Clin Nutr.* 1999;8(1):64-74. PMID:24393738
12. Faridah A, Widjanarko SB. Optimization of multilevel ethanol leaching process of porang flour (*Amorphophallus muelleri*) using response surface methodology. *Int J Adv Sci Eng Inf Technol.* 2013;3(2):74-80.
13. Dewi MS. Learning about the Solution Ability of Calcium Oxalate in *Strobilanthes crispus* Leaf Extract and Water Fraction. Universitas Andalas; 2009.
14. BPOM RI. Regulation of the Head of The Food and Drug Supervisory Agency of The Republic of Indonesia No. 7, 2014 Concerning Guidelines for *In Vivo* Non Clinical Toxicity Test; 2014.
15. Mistry K. Chronic kidney disease. *Clin Pediatr Nephrol Third Ed.* 2016;315(20):601-26.
16. Krysanti A, Widjanarko SB. Subacute toxicity testing of glucomannan (*A. muelleri* Blume) toward SGOT and sodium of wistar rats by *in vivo*. *J Pangan dan Argoin.* 2014;2(1):1-6.
17. Natalia ED, Widjanarko SB, Ningtyas DW. Acute toxicity test of glucomannan flour (*A. muelleri* Blume) toward potassium of wistar rats. *J Pangan Agroind.* 2014;2(1):132-6.
18. Aprilia V, Nurinda E, Alpina L, Hadi H, Ariftiyana S, Kurniasari Y. Reduction procedure of calcium oxalate in porang flour by maceration of *Strobilanthes crispus*; 2020. Available from: <https://pdki-indonesia.dgip.go.id/detail/S0020200668?type=patent&keyword=proses+reduksi+kalsium+oksalat>
19. OECD. OECD Guidelines for Testing of Chemicals. Test No. 420: Acute Oral Toxicity Fixed Dose Procedure; 2001. p. 1-14.
20. Hodge A, Sterner B. Toxicity classes. In: Canadian Center for Occupational Health and Safety; 2005.
21. Mundt L, dan Shanahan K. Graff's Textbook of Urinalysis and Body Fluids. Philadelphia, PA; Wolters Kluwer; 2010.
22. Harris P, Mann L, Phillips B, Webster C. Diabetes Management in General Practice Guideline for Type 2 Diabetes. Australia: Diabetes Australia; 2011.
23. Wicaksono MA. The Evaluation of Renal and Hepatic Function of Female Rats (Sprague-Dawley) as the Impact of Administration of Galohgor Jamu. Bogor Agricultural University; 2010. (In Indonesian)
24. Korth KL, Doege SJ, Park SH, Goggin FL, Wang Q, Gomez SK, et al. Medicago truncatula mutants demonstrate the role of plant calcium oxalate crystals as an effective defense against chewing insects. *Plant Physiol.* 2006;141(1):188-95. <http://doi.org/10.1104/pp.106.076737> PMID:16514014
25. Keppel J, Calissi P. Safe drug prescribing for patients with renal insufficiency. *Can Med Assoc J.* 2002;166(6):473-7. PMID:11873927
26. Albright RC Jr. Acute renal failure: A practical update. *Mayo Clin Proc.* 2001;76(1):67-74. <http://doi.org/10.4065/76.1.67> PMID:11155415
27. Wilcox CR, Whitehurst LA, Somani BK, Cook P. Kidney stone disease: An update on its management in primary care. *Br J Gen Pract.* 2020;70(693):205-6. PMID:32217603
28. Ratkalkar VN, Kleinman JG. Mechanisms of stone formation. *Clin Rev Bone Miner Metab.* 2011;9(3-4):187-97. <http://doi.org/10.1007/s12018-011-9104-8> PMID:22229020
29. Mitruka BM. Clinical Biochemical and Hematological Reference Values in Normal Experimental Animals and Normal Humans. 2nd ed. Chicago: Masson Publishing; 1981.
30. Donowarti I, Widjanarko SB, Yuniarta Y, Pudjiastuti P. Acute toxicity test of low calcium oxalate porang (*Amorphophallus muelleri* Blume) flour. *Iraqi J Agric Sci.* 2021;52(1):218-31.
31. Loeb WF, Quimby FW. The Clinical Chemistry of Laboratory Animals. London: Pergamon Press Inc.; 1989.
32. Shad JA, Brann OS. Acute hepatitis after ingestion of herbs. *South Med J.* 1999;92(11):1095-7. <http://doi.org/10.1097/00007611-199911000-00011> PMID:10586838
33. Laliberte L, Villeneuve JP. Hepatitis after the use of germander, a herbal remedy. *Can Med Assoc J.* 1996;154(11):1689-92. PMID:8646656
34. Currie BJ, Clough AR. Kava hepatotoxicity with western herbal products: Does it occur with traditional kava use? *Med J Aust.* 2003;178(9):421-2. <http://doi.org/10.5694/j.1326-5377.2003.tb05279.x> PMID:12720503

Author Queries???

- AQ1: Kindly provide author full name
- AQ2: Kindly provide department
- AQ3: Kindly provide history details
- AQ4: Kindly cite reference 30 in the text part
- AQ5: Kindly provide last accessed details
- AQ6: Kindly cite table 3 in the text part